

Comparison of Fast Spin-Echo Versus Conventional Spin-Echo MRI for Evaluating Meniscal Tears

Garyun B. Blackmon¹
Nancy M. Major
Clyde A. Helms

OBJECTIVE. We compare sensitivities of conventional spin-echo and fast spin-echo sequences in the evaluation of meniscal tears. Furthermore, we reevaluate the results from prior studies comparing these two sequences to understand why there are differing conclusions regarding the efficacy of fast spin-echo sequences as a commensurate replacement for conventional spin-echo sequences.

MATERIALS AND METHODS. We used records from a control group of 64 patients (128 menisci) who had undergone arthroscopy to determine the sensitivity of conventional spin-echo sequences for detecting meniscal tears. Two hundred sixteen consecutive patients (432 menisci) were then imaged using conventional spin-echo and fast spin-echo sequences to evaluate for meniscal tears. Both sequences were proton density-weighted with fat suppression.

RESULTS. Of the 432 menisci, 170 tears were detected on conventional spin-echo imaging. Only 128 tears were detected on the fast spin-echo sequence. The sensitivities of conventional spin-echo and fast spin-echo imaging were found to be 93% and 80%, respectively. In addition, findings from conventional spin-echo and fast spin-echo sequences were discordant for 72 menisci (17%, $p < 0.01$).

CONCLUSION. The sensitivities of conventional spin-echo and fast spin-echo imaging for detecting meniscal tears have been shown to be greater than 90% and approximately 80%, respectively. However, some authors advocate substituting conventional spin-echo imaging with fast spin-echo imaging. We urge the abandonment of fast spin-echo imaging for evaluating meniscal tears because a loss of greater than 10% in sensitivity is unacceptable.

MRI has been established as an effective technique with which to evaluate meniscal tears of the knee. Conventional spin-echo MR images have traditionally been used with reported sensitivities and specificities of 90–95% for the detection of meniscal tears [1–5]. Fast spin-echo MR images have been applied to decrease imaging time. Multiple reports have appeared in the radiology literature comparing conventional spin-echo with fast spin-echo MR images for meniscal tears [6–10]. The reports have generated differing conclusions for the efficacy of fast spin-echo sequences in detecting meniscal tears, which raises considerable controversy as to the true utility of fast spin-echo sequences. We performed this study to compare fast spin-echo images with conventional spin-echo images for the detection of meniscal tears in the knee and to reevaluate the results of prior studies to understand why they have such different conclusions.

Materials and Methods

Routine knee MRI was performed on 216 consecutive patients (432 menisci) over a 2-month period using our standard knee protocol. There were 102 females and 114 males, ages 15–70 years (average age, 40.2 years). Imaging was performed with a 1.5-T system (Signa, GE Healthcare) and a transmit-receive knee coil. The sagittal images were used to evaluate the menisci. The conventional spin-echo imaging parameters for the sagittal images were as follows: fat-suppressed proton density; TR/TE, 2,000/20; matrix, 256 × 192; 2 signal averages; 16-cm field of view; and 4-mm-thick slice with 0.4-mm gap. The imaging time for this series was 7 min 20 sec. In addition, each patient was also imaged with a sagittal fast spin-echo imaging sequence with the following parameters: fat-suppressed proton density; TR/TE_{eff}, 3,000/17; and echo-train length, 4. The remaining parameters were identical to the conventional spin-echo protocol. The imaging time for the fast spin-echo sequence was 3 min 20 sec.

The fast spin-echo images were separated from the remainder of the study and interpreted by one of

Received June 29, 2004; accepted after revision September 22, 2004.

¹All authors: Department of Radiology, Duke University Medical Center, Box 3808, Durham, NC 27710. Address correspondence to C. A. Helms (helms002@mc.duke.edu).

AJR 2005;184:1740–1743

0361–803X/05/1846–1740

© American Roentgen Ray Society

MRI of Meniscal Tears

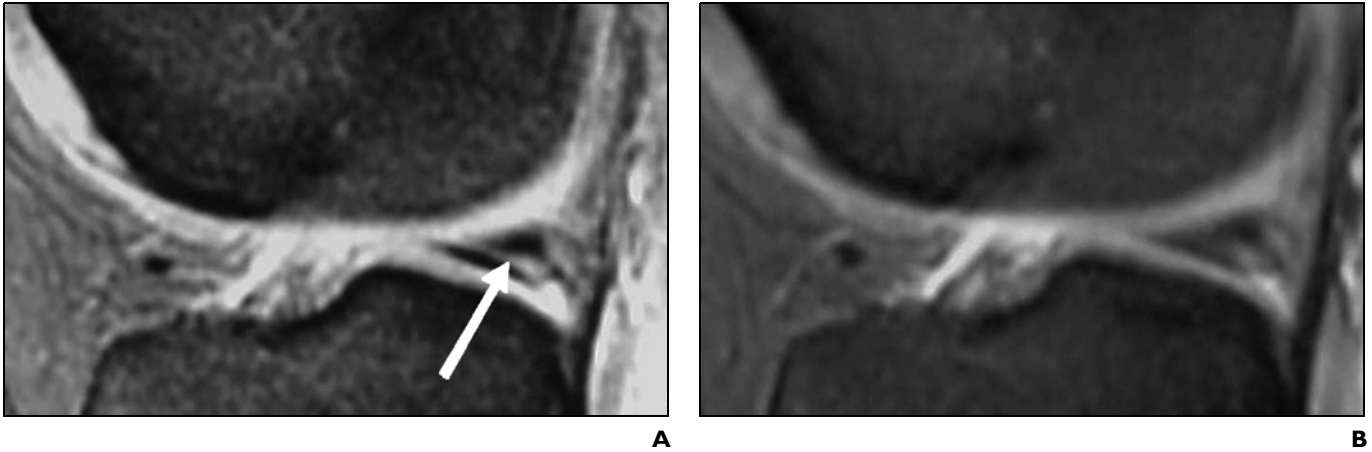


Fig. 1.—Conventional spin-echo versus fast spin-echo imaging for detection of meniscal tear in 29-year-old man.

A, Sagittal conventional spin-echo proton density-weighted MR image (TR/TE, 2,000/20) with fat suppression obtained through medial meniscus shows oblique tear of posterior horn (*arrow*).

B, Sagittal fast spin-echo proton density-weighted MR image (3,000/17) with fat suppression obtained through medial meniscus does not show meniscal tear.

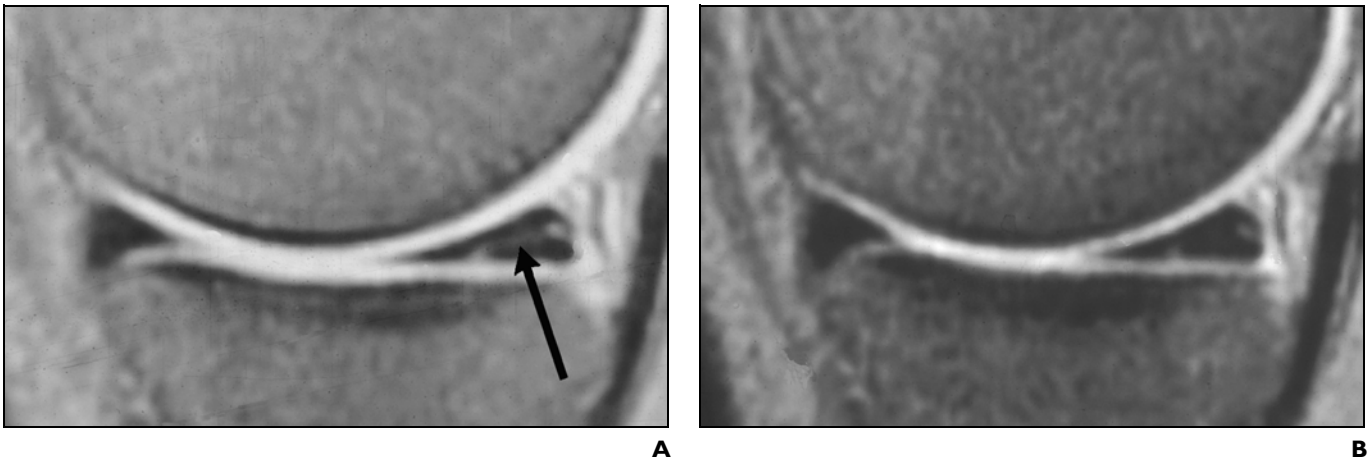


Fig. 2.—Conventional spin-echo versus fast spin-echo imaging for detection of meniscal tear in 34-year-old woman.

A, Sagittal conventional spin-echo proton density-weighted MR image (TR/TE, 2,000/20) with fat suppression obtained through medial meniscus shows oblique tear of posterior horn (*arrow*).

B, Sagittal fast spin-echo proton density-weighted MR image (3,000/17) with fat suppression obtained through medial meniscus does not show meniscal tear.

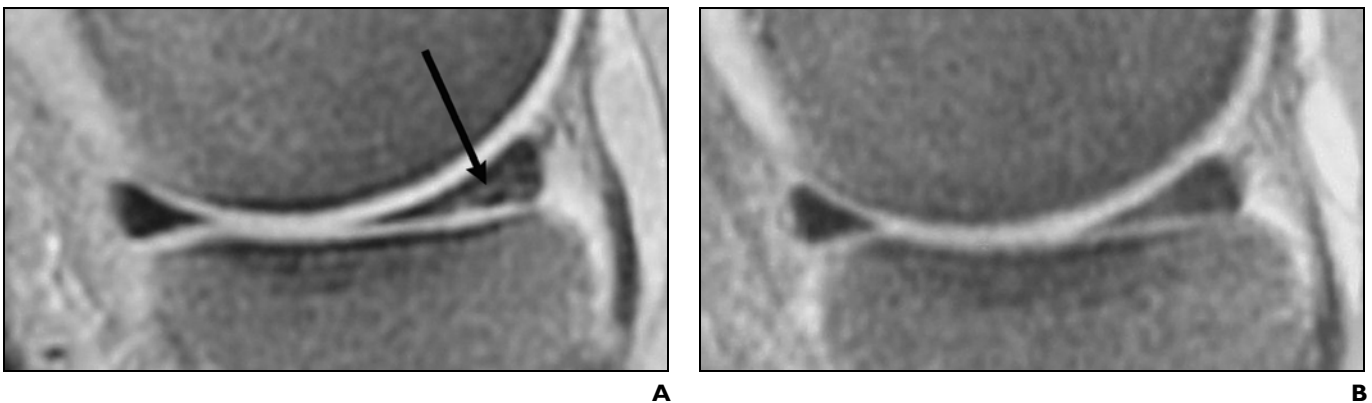


Fig. 3.—Conventional spin-echo versus fast spin-echo imaging for detection of meniscal tear in 50-year-old woman.

A, Sagittal conventional spin-echo proton density-weighted MR image (TR/TE, 2,000/20) with fat suppression obtained through medial meniscus shows complex tear of posterior horn (*arrow*).

B, Sagittal fast spin-echo proton density-weighted MR image (3,000/17) with fat suppression obtained through medial meniscus does not show meniscal tear.

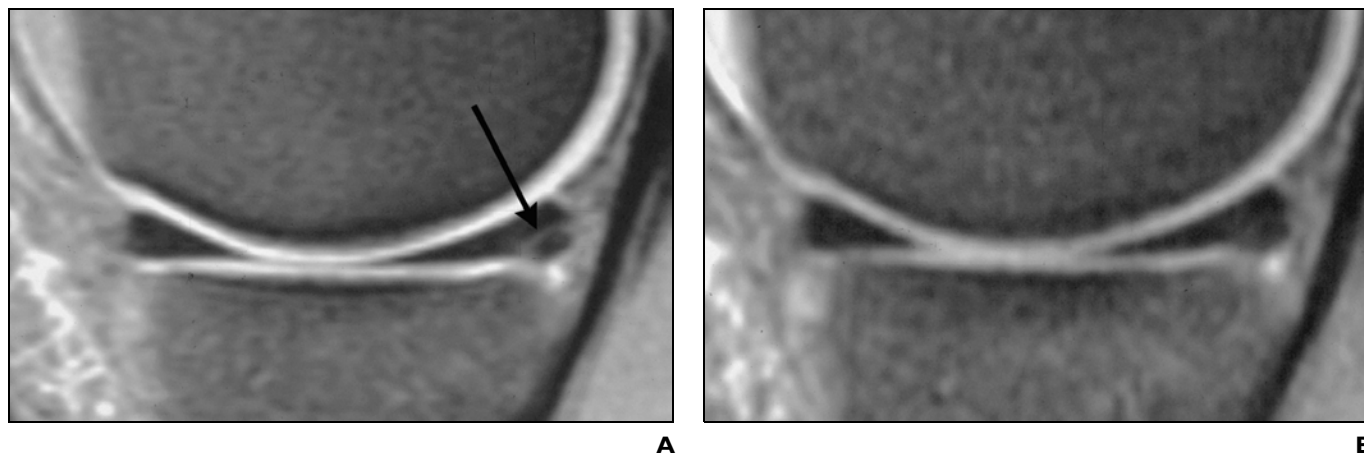


Fig. 4.—Conventional spin-echo versus fast spin-echo imaging for meniscal tear in 26-year-old man.

A, Sagittal conventional spin-echo proton density-weighted MR image (TR/TE, 2,000/20) with fat suppression obtained through medial meniscus shows oblique tear of posterior horn (arrow).

B, Sagittal fast spin-echo proton density-weighted MR image (3,000/17) with fat suppression obtained through medial meniscus does not show meniscal tear.

three board-certified and experienced musculoskeletal radiologists at least 1 month after the date of the examination. The original MR examination was interpreted in the usual manner within 24 hr of the examination by any of six experienced musculoskeletal radiologists. Comparison of the interpretations for meniscal tears was made after all 216 patients had been examined. Cases with discordant diagnoses between the conventional spin-echo and fast spin-echo examinations were then reexamined, and a consensus opinion was reached between two of the radiologists.

A control group of 64 patients (128 menisci), separate from the 216 patients in the study group, who had undergone arthroscopy were used to determine the expected sensitivity and specificity for meniscal tears using our conventional spin-echo imaging protocol. In this cohort, there were 24 women and 40 men, ages 18–65 years (average age, 36.3 years). A tear was diagnosed when linear high signal that disrupted the articular surface of the meniscus was seen on at least one of the sagittal images or if the morphology was abnormal.

Comparison of the expected sensitivity for meniscal tears was made between the conventional spin-echo and the fast spin-echo images based on the control group's sensitivity. The Student's *t* test was used to compare the results for statistical significance. Operative reports were used as the gold standard for the subset of those patients who had arthroscopy.

Results

All of the patients in the control group of 128 menisci used to establish the sensitivity and specificity of conventional spin-echo at detecting meniscal tears were also examined arthroscopically. In the control group, 49 of the 53 arthroscopically proven tears were de-

tected on conventional spin-echo imaging. Two of the menisci interpreted as having a tear on conventional spin-echo imaging were not torn at arthroscopy. Hence, the sensitivity and specificity of the conventional spin-echo sequence were 93% and 97%, respectively.

A comparison of the fast spin-echo and conventional spin-echo images of the study group of 432 menisci indicated that 170 tears (39%) were detected on the conventional spin-echo sequence and only 128 tears were detected on the fast spin-echo sequence. Taking into account expected false-negatives and false-positives generated from the control group, we found that the sensitivity of the fast spin-echo sequence was 80%. Furthermore, conventional spin-echo and fast spin-echo interpretations were discordant in 72 of the 432 menisci. This corresponds with a statistically significant discordance of 17% ($p < 0.01$). Among the 72 cases with discordant interpretations, 42 tears were not identified on fast spin-echo but were readily diagnosed on conventional spin-echo (Figs. 1–4). Of the 42 torn menisci that could not be detected on fast spin-echo images, 27 (64%) were medial tears and 15 (36%) were lateral tears. The remaining 30 menisci showed abnormal meniscal signal on fast spin-echo images that was not present on conventional spin-echo images.

Discussion

A review of six studies, including our study, focusing on sensitivities of fast spin-echo sequences in the detection of meniscal tears has shown a distinct discrepancy be-

tween the sensitivities of fast spin-echo and conventional spin-echo sequences (Table 1). The sensitivities for detecting a meniscal tear on fast spin-echo sequences average approximately 80%, whereas the sensitivities of the conventional spin-echo sequences in the listed studies average approximately 90%. As mentioned earlier, other studies that evaluate the sensitivity of conventional spin-echo imaging alone have reported sensitivities ranging from 90% to 95%.

In addition, we found the discordance between conventional spin-echo and fast spin-echo sequences in our study to be 17%, which is a considerable percentage of incongruity. Both the group of false-positive and false-negative meniscal tears on fast spin-echo imaging may be attributed in part to blurring. It has been postulated that abnormal intrameniscal signal in a fast spin-echo sequence may appear to extend to the meniscal surface secondary to blurring and be incorrectly interpreted as a tear [6]. Alternatively, the increased blurring and decreased resolution associated with fast spin-echo imaging can contribute to false-negative interpretations. Blurring is most evident with short- TE_{eff} sequences. However, short- TE_{eff} sequences are most proficient for detecting meniscal abnormalities [2, 11]. Blurring is also more conspicuous with longer echo-train lengths, such as those incorporated in fast spin-echo imaging protocols [12, 13]. We chose an echo-train length of 4 to minimize blurring.

An MR image is created after a complete set of raw data points fills the k-space matrix,

TABLE 1 Reported Sensitivities of Fast Spin-Echo and Conventional Spin-Echo Sequences for the Detection of Meniscal Tears

Authors [reference number]	No. of Menisci	Sensitivity (%)	
		Fast Spin-Echo Sequence	Conventional Spin-Echo Sequence
Rubin et al. [6]	129	65	a
Anderson et al. [7]	30	83	89
Escobedo et al. [8]	38	82	88
Cheung et al. [9]	578	82	b
Blackmon et al. (current study)	432	80	93
Kowalchuk et al. [10]	200	82	a

^aThe conventional spin-echo sequence was used as the gold standard.

^bThe sensitivity of the conventional spin-echo sequence was not evaluated. Arthroscopy was used as the gold standard.

which is a grid composed of spatial frequencies. Conventional spin-echo sequences accumulate a single line of k-space during transverse magnetization decay after each 90° radiofrequency excitation. The single line of k-space data is obtained at a particular TE and the spatial frequencies are weighted the same.

The appeal of fast spin-echo includes faster imaging time and the potentially associated decrease in patient motion artifact. The fast spin-echo sequence saves imaging time by decreasing the number of radiofrequency excitations required to complete the k-space matrix. With each initial 90° radiofrequency excitation, more than one 180° refocusing radiofrequency pulse is applied. Therefore, several k-space lines are acquired with each radiofrequency excitation, instead of only one as with conventional spin-echo sequences. The echo-train length represents the number of 180° refocusing radiofrequency pulses and is also the factor by which imaging time can be truncated. The different generated echoes have different spatial frequencies and weighting. Depending on how the echoes are arranged in the k-space matrix and the time to echo (i.e., the TE), image contrast and resolution may be manipulated.

Although there are proponents for fast spin-echo imaging as a commensurate substitute for conventional spin-echo imaging, there is clearly a significant difference in the sensitivities between the two imaging sequences. In addition, a more qualitative preference for conventional spin-echo images was also observed by the radiologists in the study by Kowalchuk et al. [10]. The

benefit of faster imaging time should not outweigh the diagnostic inferiority of fast spin-echo images.

The limitations of our study include the use of expected conventional spin-echo sensitivities for meniscal tears that were established from a control group based on arthroscopy as the gold standard. In addition, the gold standards used to calculate sensitivities varied among the studies listed in Table 1 between conventional spin-echo and arthroscopy. However, multiple other studies have similarly used conventional spin-echo as the standard with which to compare fast spin-echo. The sensitivity of conventional spin-echo is well documented, and our results concur with the established sensitivities. Nonetheless, a prospective study directly comparing conventional spin-echo and fast spin-echo sequences with arthroscopy would provide a more precise data set. Although the validity of arthroscopic detection of meniscal tears as a gold standard has been debated [14], it remains the most widely accepted method of meniscal tear confirmation.

In conclusion, we strongly urge abandonment of fast spin-echo sequences for evaluating the menisci. In our study of 432 menisci, we would have failed to detect 42 tears if we had relied on the fast spin-echo sequence, which is unacceptable. The varying opinions regarding the utility of fast spin-echo sequences seem to be based on differing conclusions derived from the studies rather than differences in the results generated from the studies, because all published studies show an approximately 80% sensitivity for meniscal tears with the fast spin-echo sequence.

References

1. Crues JJ, Mink J, Levy T, Lotysch M, Stoller D. Meniscal tears of the knee: accuracy of MR imaging. *Radiology* 1987;164:445-448
2. Mink J, Levy T, Crues JL. Tears of the anterior cruciate ligament and menisci of the knee: MR imaging evaluation. *Radiology* 1988;167: 769-774
3. Boeree NR, Watkinson AF, Ackroyd CE, Johnson C. Magnetic resonance imaging of meniscal and cruciate injuries of the knee. *J Bone Joint Surg Br* 1991;73:452-457
4. De Smet AA, Graf BK. Meniscal tears missed on MR imaging: relationship to meniscal tear patterns and anterior cruciate ligament tears. *AJR* 1994;162:905-911
5. Mackenzie R, Palmer CR, Lomas DJ, Dixon AK. Magnetic resonance imaging of the knee: diagnostic performance studies. *Clin Radiol* 1996; 51:251-257
6. Rubin DA, Kneeland JB, Listerud J, Underberg-Davis SJ, Dalinka MK. MR diagnosis of meniscal tears of the knee: value of fast spin-echo vs conventional spin-echo pulse sequences. *AJR* 1994;162:1131-1135
7. Anderson MW, Raghavan N, Seidenwurm DJ, Greenspan A, Drake C. Evaluation of meniscal tears: fast spin-echo versus conventional spin-echo MR imaging. *Acad Radiol* 1995;2: 209-214
8. Escobedo EM, Hunter JC, Zink-Brody GC, Wilson AJ, Harrison SD, Fisher DJ. Usefulness of turbo spin-echo MR imaging in the evaluation of meniscal tears: comparison with a conventional spin-echo sequence. *AJR* 1996;167: 1223-1227
9. Cheung L, Li K, Hollett M, Bergman A, Hefkens R. Meniscal tears of the knee: accuracy of detection with fast spin-echo MR imaging and arthroscopic correlation in 293 patients. *Radiology* 1997;203:508-512
10. Kowalchuk RM, Kneeland JB, Dalinka MK, Siegelman ES, Dockery WD. MRI of the knee: value of short echo time fast spin-echo using high performance gradients versus conventional spin-echo imaging for the detection of meniscal tears. *Skeletal Radiol* 2000;29:520-524
11. Rubin DA, Paletta GA Jr. Current concepts and controversies in meniscal imaging. *Magn Reson Imaging Clin N Am* 2000;8:243-270
12. Constable R, Anderson A, Zhong J, Gore J. Factors influencing contrast in fast spin-echo MR imaging. *Magn Reson Imaging* 1992;10:497-511
13. Piraino D, Hardy P, Schils J, Richmond B, Tkach J, Belhobek G. Fast spin-echo imaging of the knee: factors influencing contrast. *J Magn Reson Imaging* 1993;3:835-842
14. Quinn SF, Brown TF. Meniscal tears diagnosed with MR imaging versus arthroscopy: how reliable a standard is arthroscopy? *Radiology* 1991;181:843-847