

In vivo experiences with magnetic resonance imaging scans in Vibrant Soundbridge type 503 implantees

I TODT¹, P MITTMANN¹, A ERNST¹, S MUTZE², G RADEMACHER²

Departments of ¹Otolaryngology, and ²Radiology, Unfallkrankenhaus Berlin, Germany

Abstract

Objective: To observe the effects of magnetic resonance imaging scans in Vibrant Soundbridge 503 implantees at 1.5T *in vivo*.

Methods: In a prospective case study of five Vibrant Soundbridge 503 implantees, 1.5T magnetic resonance imaging scans were performed with and without a headband. The degree of pain was evaluated using a visual analogue scale. Scan-related pure tone audiogram and audio processor fitting changes were assessed.

Results: In all patients, magnetic resonance imaging scans were performed without any degree of pain or change in pure tone audiogram or audio processor fitting, even without a headband.

Conclusion: In this series, 1.5T magnetic resonance imaging scans were performed with the Vibrant Soundbridge 503 without complications. Limitations persist in terms of magnetic artefacts.

Key words: Magnetic Resonance Imaging; Postoperative Complications; Middle Ear Implants

Introduction

Magnetic resonance imaging (MRI) scanners have become a regular diagnostic tool in hospitals and out-patient departments, with specific advantages over other radiological options. It has been estimated that 50–75 per cent of pacemaker wearers will need to have an MRI during their lifetime.¹ Investigation of the MRI behaviour of implantable hearing systems is also very important.

Although cochlear implant systems have their brand-specific advantages and disadvantages in terms of demagnetisation, pain occurrence and magnet dislocations,^{2–4} the situation for active middle-ear implants is different. In contrast to the non-MRI-compatible active middle-ear systems (i.e. the middle-ear transducer, Carina and direct acoustic cochlear stimulator (Cochlear, Sydney, Australia) systems), the Vibrant Soundbridge[®] implant system is the only MRI-compatible system. The Vibrant Soundbridge requires more detailed observations to determine its MRI behaviour.

The Vibrant Soundbridge contains two magnets: the audio processor containing a holding magnet, and the magnetic floating mass transducer. As the previous Vibrant Soundbridge type 502 generation showed side effects, including pain and transfer function affecting floating mass transducer dislocations,⁵ the new Vibrant Soundbridge type 503 generation was designed to offer better compatibility with MRI scanning. In order to prevent implant receiver dislocations caused

by the magnetic field, wings were attached to the body of the implant to allow the implant receiver to be screwed into the skull. Additionally, the internal floating mass transducer magnet was changed to a tri-polar magnet to direct itself in the case of an MRI scan in the magnetic field, in order to minimise torsion-related floating mass transducer movements.⁶

The current study aimed to investigate the consequences of an MRI scan performed in patients implanted with the Vibrant Soundbridge 503 system.

Materials and methods

Five patients implanted with a 503 Vibrant Soundbridge between 2014 and 2016 underwent an MRI scan of the head (Ingenia MRI system; Philips Medical Systems, Best, Netherlands). A headband was attached before the scan. If the first scan was performed without any complications in terms of pain, discomfort, hearing ability with the audio processor, and hearing ability without the audio processor, the same MRI scan was repeated without a headband.

The imaging parameters for the two-dimensional T2-weighted turbo spin echo sequences were: repetition time = 3300 ms, echo time = 120 ms, slice thickness = 1.5 mm, reconstruction resolution of 0.55 × 0.55 × 1.5 mm, field of view = 120 × 120, 12 slices. The imaging parameters for the two-dimensional T1-weighted turbo spin echo sequences were: repetition

time = 550 ms, echo time = 20 ms, slice thickness = 3 mm, reconstruction resolution of $0.23 \times 0.23 \times 3$ mm, field of view = 120×120 , 20 slices.

A pure tone audiogram was acquired before the first scan and after the second MRI scan. Individual attachments of the floating mass transducer are described in Table I.

The transfer function of the Vibrant Soundbridge was evaluated subjectively.

The study was reviewed and supported by the institutional review board for Unfallkrankenhaus Berlin ('IRB-UKB-HNO-2016/11'), and has been conducted according to the principles expressed in the Declaration of Helsinki. This study was supported by Med-El, Innsbruck, Austria.

Results

After the first series of scans, all five patients with a headband reported no pain related to the attachment of the headband. During scanning, the five patients showed no pain as evaluated using the visual analogue scale. Subjective hearing without the audio processor was unchanged, and even hearing with the audio processor evaluated by pure tone audiogram was unchanged.

In the second series of scans performed without the headband, no pain was reported. During scanning, all patients reported no pain as evaluated using a visual analogue scale. Hearing measured without the audio processor was unchanged, and, again, even hearing with the audio processor was unchanged compared to pre-scan assessment (Table II). Magnet strength was subjectively unchanged in all cases.

The two Vibrant Soundbridge system magnets caused scanning artefacts that consisted of two artefact centres. The floating mass transducer related centre made assessment of the internal auditory canal and cochlea impossible (Figure 1).

Discussion

The MRI behaviour of implants is of increasing importance, as the use of MRI scans is widespread as a common diagnostic radiological tool, and the number of patients with active middle-ear implants is rising.

Observations of the MRI behaviour of active middle-ear implants are rare. Apart from studies on the Soundtec systems,⁷ only a few observations of the Vibrant Soundbridge have been published.

TABLE I
INDIVIDUAL ATTACHMENTS OF VIBRANT
SOUNDBRIDGE

Patient number	Date performed	Attachment area (type)
1	18 Nov 16	Oval window ('OW')
2	1 Dec 16	Short process of incus ('SP')
3	1 Dec 16	Head of stapes ('CliP')
4	8 Dec 16	Short process of incus ('SP')
5	9 Dec 16	Head of stapes ('CliP')

TABLE II
MEAN HEARING THRESHOLDS PRE- AND POST-
SCANNING

Assessment time	Frequency (kHz)			
	0.5	1	2	4
Pre-operation				
– Mean	30	33.3	48.3	63.3
–SDM	8.3	7.5	5.8	10.7
Post-operation				
–Mean	33.3	35	46.6	58.3
–SDM	6.7	5	5.9	12.1

Data represent hearing thresholds (in dB). SDM = standard deviation of the mean

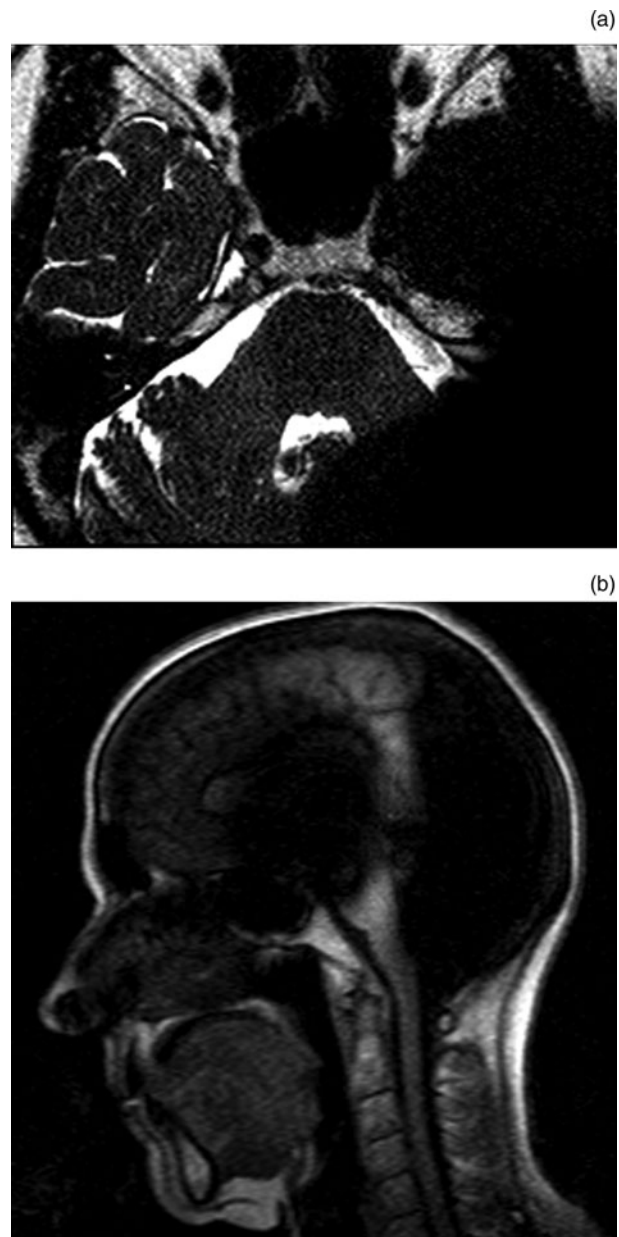


FIG. 1

Magnetic resonance imaging artefact of a Vibrant Soundbridge 503 system in the (a) axial and (b) sagittal planes.

The Vibrant Soundbridge 502 was initially investigated *in vitro*. It was observed that changes can occur to the floating mass transducer position in the middle ear and to the transfer function, but no disarticulation of the ossicular chain was found at 1.5 T.^{8,9}

Clinically, it was shown in a group of 63 Vibrant Soundbridge 502 implantees that 13 implantees (20.6 per cent) had undergone 19 MRI scans.⁵ Twelve of the patients were implanted with the floating mass transducer fixed to the long process of the incus. One patient was bilaterally implanted with the floating mass transducer attached to the stapes head. The further occurrence of major side effects such as pain (41.7 per cent), the need to refit (50 per cent) or an operative relocation of the floating mass transducer (16.7 per cent) was recorded. Three patients (25 per cent) described a 'loud bang' during the scan, and two patients (17 per cent) complained of a loud, continuous noise.

In a second clinical study of Vibrant Soundbridge 502 implantees with a floating mass transducer alternatively attached, four patients underwent five MRI scans.¹⁰ Complications included pain at the receiver site and a change in transfer function in one patient.

The observed side effects led to changes in the design of the type 502 implant, including a tri-polar design of the floating mass transducer magnet and the option to fix the receiver with a screw.

Because magnetic field forces lead to torsional force on the receiver implant magnet, which turns up the magnet/implant, pain occurs at the scalp. Screws prevent such movement and thus the accompanying pain. The use of a tri-polar floating mass transducer magnet eliminates torsional and demagnetisational forces on the magnet in the magnetic field.

A recent temporal bone study of the Vibrant Soundbridge 503 implant showed that neither dislocation of the floating mass transducer, disarticulation of the ossicular chain nor a change in transfer function occurs at different coupling sites of the floating mass transducer.⁶ Likewise, the implant function is not affected by the scan.

- **Magnetic resonance imaging (MRI) behaviour of active middle-ear implants is problematic in terms of pain, transfer function and artefacts**
- **With the new generation of implants, MRI behaviour has improved, but artefact-related limitations persist**

This experimental finding is consistent with the clinical observations made in our study. Neither the transfer function, indicating dislocation of the floating mass transducer, nor hearing without the audio processor were changed by the scan. Pain as the most frequent complication^{5,10} was not observed, either with or without a headband, which is related to the internal screw fixation of the implant.

The artefacts of the receiver implant and the floating mass transducer persist, despite the change in design of the Vibrant Soundbridge 503. Even a positionally changed or artefact-reduced MRI sequence would not allow an accurate assessment of the internal auditory canal or the cochlea, because the floating mass transducer artefact does not allow any variations in middle-ear position.

Limitations concerning interpretation of the results include the fact that not all of the various coupling opportunities of the floating mass transducer in the middle ear were observed. However, it can be assumed that the new construction of the floating mass transducer and its expected behaviour in the MRI scanner are not dependent on the method of coupling.

Conclusion

Magnetic resonance imaging was performed with the Vibrant Soundbridge 503 implant *in vivo* without complications. Limitations persist in terms of magnetic artefacts.

References

- 1 Kalin R, Stanton MS. Current clinical issues for MRI scanning of pacemaker and defibrillator patients. *Pacing Clin Electrophysiol* 2005;**28**:326–8.
- 2 Nospes S, Mann W, Keilmann A. Magnetic resonance imaging in patients with magnetic hearing implants: overview and procedural management [in German]. *Radiologe* 2013;**53**:1026–32.
- 3 Grupe G, Wagner J, Hofmann S, Stratmann A, Mittmann P, Ernst A *et al*. Prevalence and complications of MRI scans of cochlear implant patients [in German]. *HNO* 2016;**64**:156–62.
- 4 Kim BG, Kim JW, Park JJ, Kim SH, Kim HN, Choi JY. Adverse events and discomfort during magnetic resonance imaging in cochlear implant recipients. *JAMA Otolaryngol Head Neck Surg* 2015;**141**:45–52.
- 5 Todt I, Wagner J, Goetze R, Scholz S, Seidl R, Ernst A. MRI scanning in patients implanted with a Vibrant Soundbridge. *Laryngoscope* 2011;**121**:1532–5.
- 6 Schnabl J, Wolf-Magele A, Pok SM, Hirtler L, Heinz G, Sprinzl GM. Magnetic resonance imaging compatibility of a new generation of active middle ear implant: a clinically relevant temporal bone laboratory study. *Otol Neurotol* 2016;**37**:222–7.
- 7 Dyer RK Jr, Nakmali D, Dormer KJ. Magnetic resonance imaging compatibility and safety of the SOUNDTEC Direct System. *Laryngoscope* 2006;**116**:1321–33.
- 8 Todt I, Rademacher G, Wagner F, Schedlbauer E, Wagner J, Basta D *et al*. MRI safety of the floating mass transducer. *Otol Neurotol* 2010;**9**:1435–40.
- 9 Jesacher MO, Kiefer J, Zierhofer C, Fauser C. Torque measurements of the ossicular chain: implication on the MRI safety of the hearing implant Vibrant Soundbridge. *Otol Neurotol* 2010;**31**:676–80.
- 10 Renninger D, Ernst A, Todt I. MRI scanning in patients implanted with a round window or stapes coupled floating mass transducer of the Vibrant Soundbridge. *Acta Otolaryngol* 2016;**136**:241–4.

Author for correspondence:

Dr Ingo Todt,
Department of Otolaryngology,
Unfallkrankenhaus Berlin,
Warener Str. 7,
D-12683 Berlin, Germany

Fax: +49 30 5681 4303
E-mail: todt@gmx.net

Dr I Todt takes responsibility for the integrity of the content of the paper
Competing interests: None declared
