

Pictorial Essay

Two-Dimensional Time-of-Flight MR Angiography of the Lower Extremities: Artifacts and Pitfalls

John A. Kaufman¹, Douglas McCarter^{1,2}, Stuart C. Geller¹, Arthur C. Waltman¹

MR angiography is a promising method for noninvasive imaging of peripheral vascular disease. Two-dimensional (2D) time-of-flight (TOF) MR angiography is the most common technique used for evaluation of the pelvic and infrainguinal arteries [1]. This pictorial essay presents pitfalls and artifacts that may be encountered during clinical MR angiography of the lower extremities. Knowledge of these imaging findings is essential for accurate interpretation of peripheral 2D TOF MR angiography.

MR imaging was performed in a 1.5-T Signa scanner (General Electric Medical Systems, Milwaukee, WI). The 2D TOF MR angiograms were acquired in the axial plane in standard body, head, or extremity coils with a spoiled gradient-recalled pulse sequence and flip angles of 45° for the pelvis and 60° for the extremities. The slice thickness was 2.9 mm and field of view was 32 cm in the body coil; 2.0 mm and 22 cm, respectively, in the head coil; and 2.0 mm and 16 cm, respectively, in the extremity coil. Imaging parameters were TR range/TE range, 29–32/6.7–7.1; first-order gradient moment nulling (flow compensation); tracking inferior saturation (usually 20 mm below the slice); 256 × 128 matrix; one excitation; and phase encoding from anterior to posterior. Three-dimensional sequences were acquired in the body coil using a fast spoiled gradient-

recalled or spoiled gradient-recalled pulse sequence; 45–60° flip angle; TR range/TE range, 10.6–32/2.1–6.9; 28–60 partitions, 2–2.5 mm thick; 36-cm field of view; 256 × 128–256 matrix; one excitation; and dynamic gadolinium enhancement in all cases [2].

Signal loss in a patent vessel from saturation of in-plane flow is one of the most common pitfalls in 2D TOF MR angiography. When the path of a vessel causes blood to re-

main in the imaging slice for a sufficient time, progressive signal loss results because of saturation of the vascular spins by the same pulses that saturate signal from the stationary background tissues. This loss of signal may simulate an occlusion or stenosis. Saturation of in-plane flow occurs typically in two anatomic areas: tortuous iliac arteries and the proximal anterior tibial artery (Fig. 1). Signal loss is accentuated by the maximum-inten-

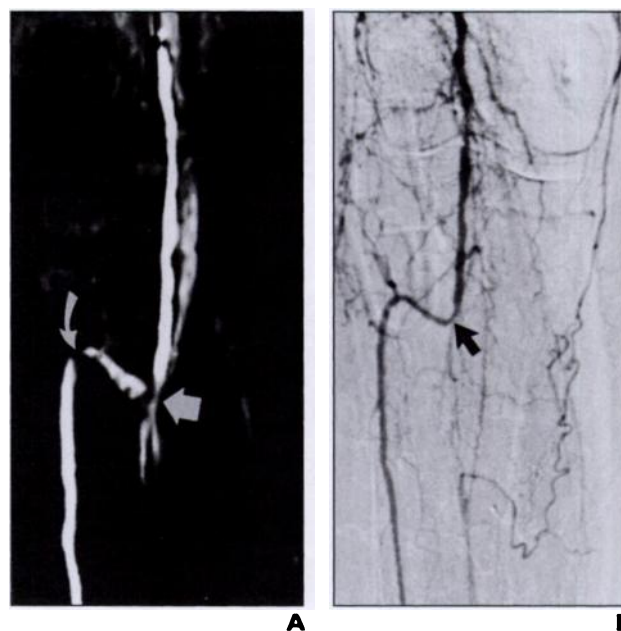


Fig. 1.—Signal loss due to in-plane flow saturation at origin of anterior tibial artery in 76-year-old woman with pain at rest.

A. Coronal reformatted two-dimensional time-of-flight MR angiogram shows severe origin stenosis (*straight arrow*) and second proximal stenosis (*curved arrow*) within right anterior tibial artery. Faint venous signal is seen medial to popliteal artery.

B. Digital subtraction angiogram shows single moderate stenosis (*arrow*) at origin of anterior tibial artery. No stenosis is present in proximal portion of vessel.

Received November 17, 1997; accepted after revision January 29, 1998.

¹ Department of Radiology, Harvard Medical School, Massachusetts General Hospital, 32 Fruit St., Boston, MA 02114. Address correspondence to J. A. Kaufman.

² Present address: Department of Radiology, Glasgow Royal Infirmary, 16 Alexandra Parade, Glasgow, G31 2ER, Scotland.

AJR 1998;171:129–135 0361–803X/98/1711–129 © American Roentgen Ray Society

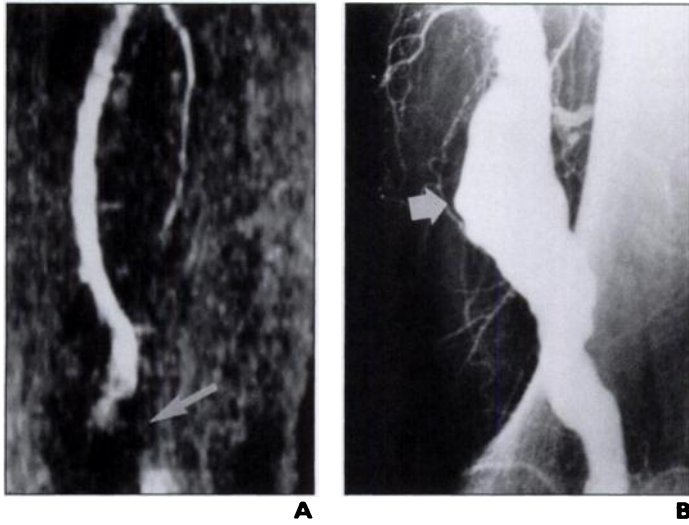


Fig. 2.—Signal loss due to turbulence and slow flow in 71-year-old man with known left popliteal artery aneurysm.
A, Coronal maximum intensity projection of two-dimensional time-of-flight MR angiogram of left upper leg. Note loss of signal (*arrow*) within aneurysm, which could be caused by saturation of slow flow, intravoxel phase dispersion due to turbulence, or thrombosis of aneurysm.
B, Conventional contrast angiogram shows that aneurysm (*arrow*) is patent.

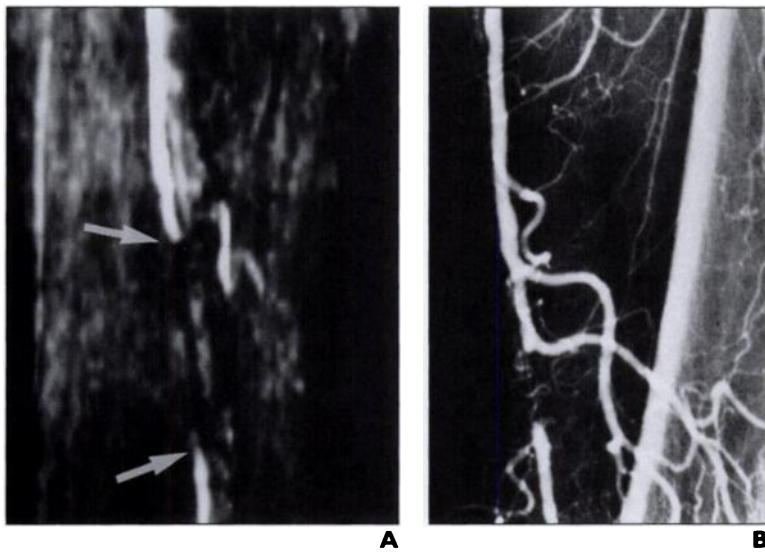


Fig. 3.—Saturation of retrograde flow distal to superficial femoral artery occlusion in 65-year-old man.
A, Coronal maximum intensity projection of two-dimensional time-of-flight MR angiogram of thigh in patient with claudication. Note signal loss (*arrows*) over distance of 6 cm in distal superficial femoral artery.
B, Conventional contrast-enhanced angiogram reveals approximately 1-cm occlusion. Vessel distal to occlusion is reconstituted in retrograde fashion by hypertrophied muscular branches from superficial femoral artery.

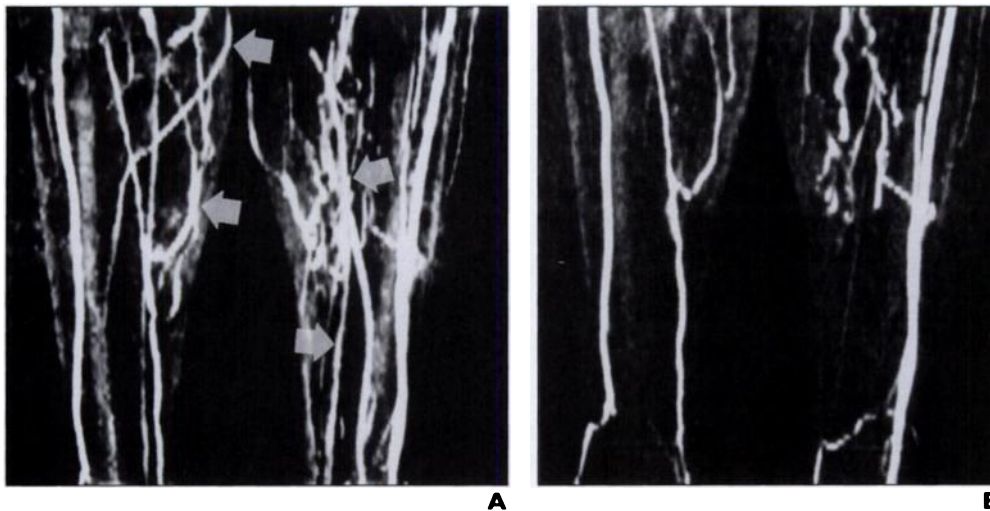
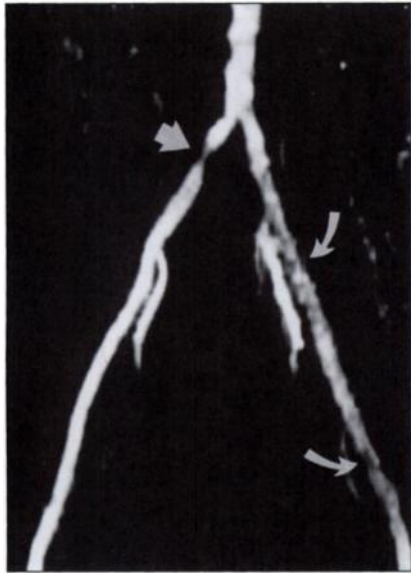
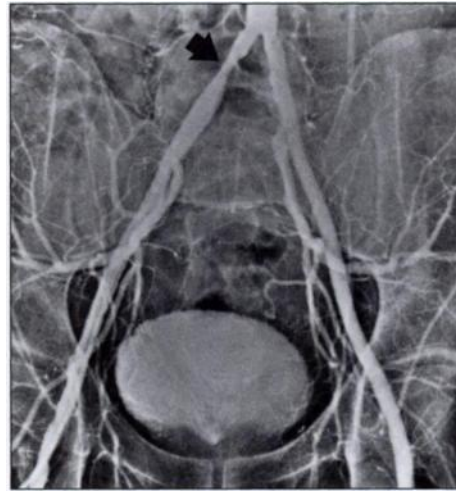


Fig. 4.—Impact of saturation band distance from imaging slice in 58-year-old man with claudication.
A, Coronal maximum intensity projection of two-dimensional time-of-flight MR angiogram of calves. Saturation gap is set at 20 mm below imaging slice. Note extensive and confusing visualization of veins (*arrows*).
B, Coronal maximum intensity projection of two-dimensional time-of-flight MR angiogram repeated with saturation gap set at 5 mm below imaging slice shows that saturation of venous signal is improved.

MR Angiography of the Lower Extremities



A

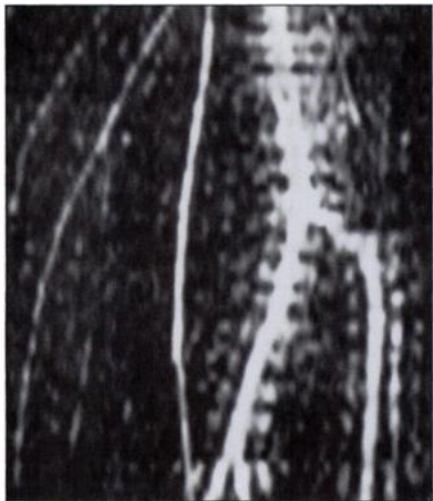


B

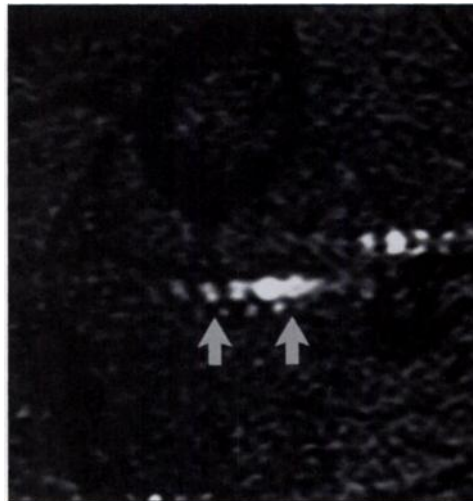
Fig. 5.—Diminished signal from flow in healthy vessels relative to diseased vessels in 53-year-old man with right-sided claudication.

A. Coronal maximum intensity projection of two-dimensional time-of-flight MR angiogram of pelvis. Note severe focal, common iliac artery stenosis on right (*straight arrow*). Signal in left iliac arteries (*curved arrows*) is diminished in comparison with right, although patient was known to have normal findings of noninvasive studies on left.

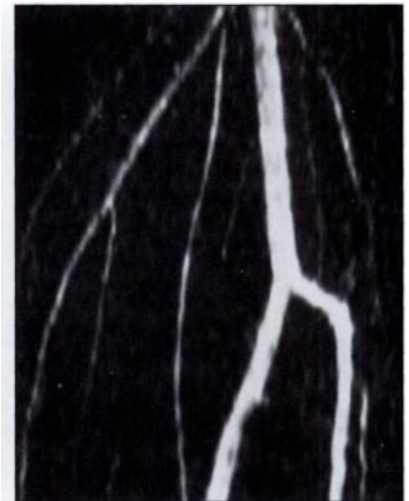
B. Conventional contrast angiogram shows moderate stenosis of right common iliac artery (*arrow*) and healthy iliac arteries on left. Overestimation of severity of stenoses is characteristic of unenhanced MR angiography; gradient across this lesion measured 30 mm Hg at rest and patient's symptoms resolved after angioplasty.



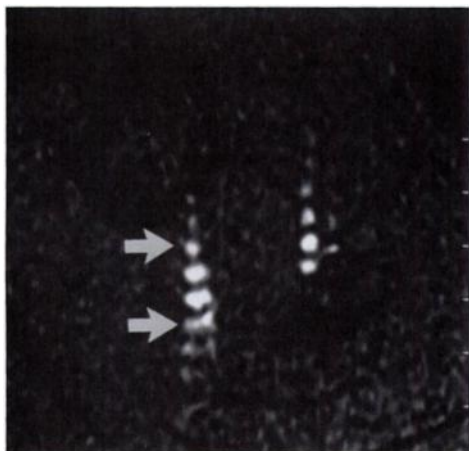
A



B



C



D

Fig. 6.—Pulsatility artifacts in phase-encoding direction in two-dimensional (2D) time-of-flight (TOF) MR angiogram of popliteal artery in healthy volunteer.

A. Coronal maximum intensity projection (MIP) of 2D TOF MR angiogram with phase encoding in right to left direction. Note prominent ghosting artifacts adjacent to run-off arteries caused by pulsatility.

B. Axial 2D TOF source image with phase encoding in right to left direction. Ghosting artifacts (*arrows*) are distributed from right to left.

C. Coronal MIP of 2D TOF MR angiogram with phase encoding in anteroposterior direction. No ghosting artifact is seen in this projection.

D. Axial 2D TOF source image with phase encoding in anteroposterior direction. Note ghosting artifacts (*arrows*) are present but were not visible on coronal MIP.

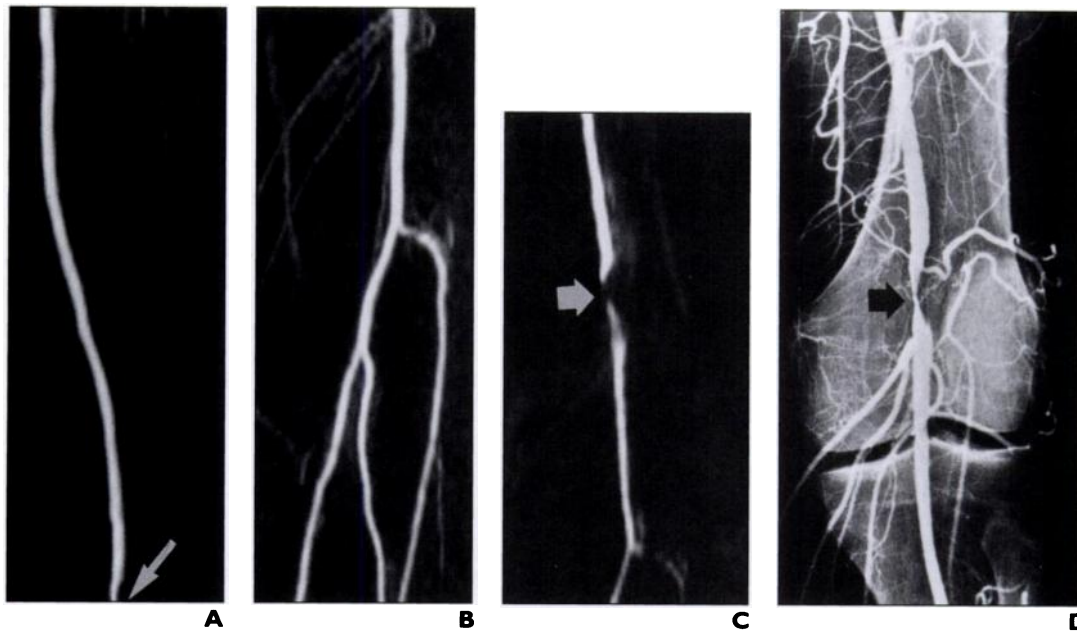


Fig. 7.—Importance of careful patient positioning is indicated in 58-year-old woman with left calf claudication.
A, Coronal maximum intensity projection (MIP) of two-dimensional time-of-flight MR angiogram of left thigh (obtained in body coil). Visible on lower edge of image is top of stenosis (*arrow*) in left above-knee popliteal artery.
B, Coronal MIP of next station in runoff (obtained in head coil). Left popliteal artery is normal, suggesting lack of adequate overlap with previous image.
C, Further two-dimensional time-of-flight MR angiogram of popliteal arteries. Focal, severe left popliteal artery stenosis (*arrow*) is clearly revealed on coronal MIP. Signal loss at origin of anterior tibial artery is caused by in-plane flow.
D, Conventional contrast angiogram confirming left popliteal artery stenosis (*arrow*).

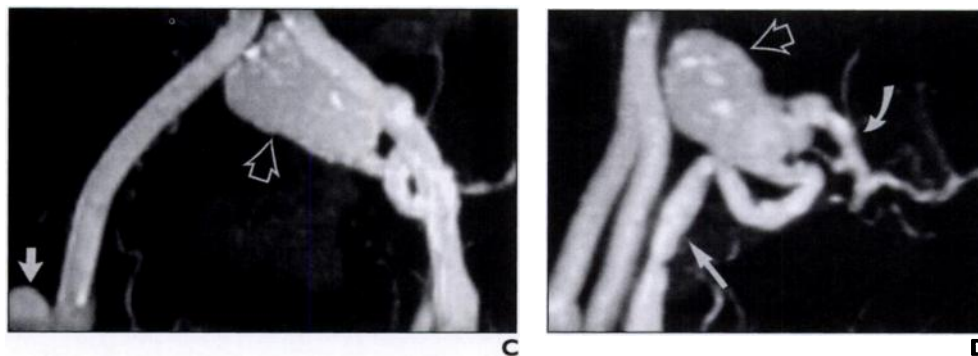
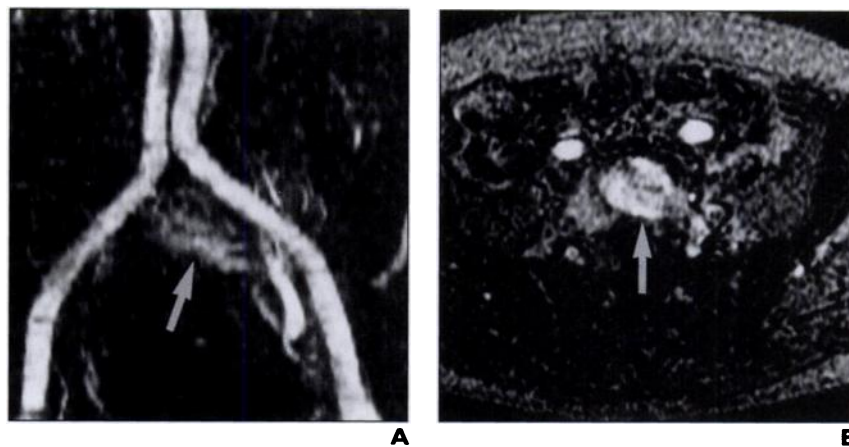


Fig. 8.—MR angiogram of pelvis of 77-year-old man with prior repair of abdominal aortic aneurysm.
A, Coronal maximum intensity projection (MIP) of two-dimensional (2D) time-of-flight (TOF) MR angiogram of pelvis. Faint area of increased signal intensity (*arrow*) is present in mid pelvis.
B, Axial slice from 2D TOF MR angiogram shows lobulated structure (*arrow*) with faint signal intensity posterior to graft.
C, Coronal MIP from gadolinium-enhanced three-dimensional MR angiogram shows that structure is large aneurysm (*open arrow*). Also note small right distal anastomotic pseudoaneurysm (*solid arrow*). Neither aneurysm was well seen on 2D TOF MR angiogram because of saturation of flow and phase dispersion.
D, Oblique MIP of gadolinium-enhanced three-dimensional MR angiogram shows that large aneurysm (*open arrow*) originates from left common iliac artery bifurcation, supplied by retrograde flow from left external iliac artery (*straight solid arrow*), with outflow via left internal iliac artery (*curved arrow*). Graft is anterior to native vessels. Distal anastomoses of aortofemoral graft are constructed in “onlay” fashion to allow retrograde perfusion of pelvic vessels.

MR Angiography of the Lower Extremities

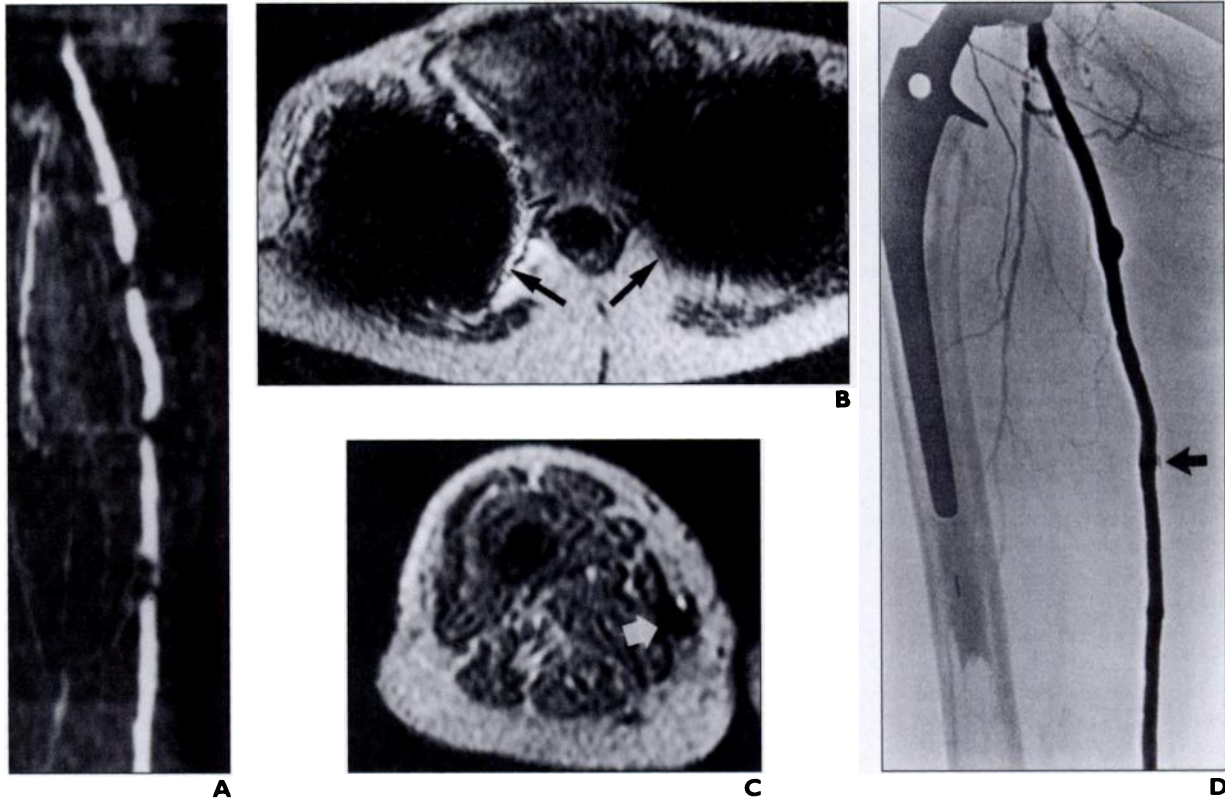


Fig. 9.—Signal loss due to metal susceptibility artifact in right thigh of 71-year-old woman with femoropopliteal saphenous vein bypass graft and bilateral hip prostheses. **A**, Coronal maximum intensity projection of two-dimensional time-of-flight MR angiogram of right thigh shows signal loss in proximal graft and at multiple points in graft. Graft had excellent flow on noninvasive studies. **B**, Axial source image from two-dimensional time-of-flight MR angiogram shows large susceptibility artifacts (*arrows*) from hip prostheses. **C**, Axial source image from right thigh shows loss of signal due to susceptibility artifact from surgical clip (*arrow*) adjacent to graft. **D**, Digital subtraction angiogram of right thigh reveals patent graft, hip prosthesis, and surgical clip (*arrow*) adjacent to graft. Additional clips were visible in oblique view (not shown).

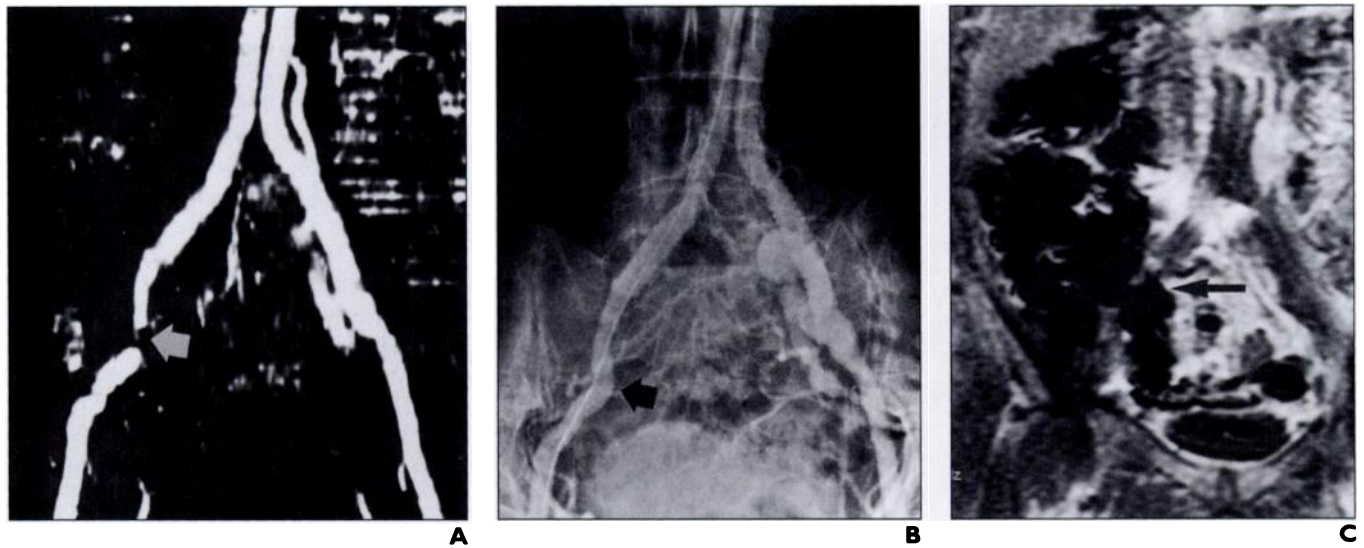


Fig. 10.—Signal loss due to susceptibility artifact from bowel gas in 73-year-old man with aortobiliac graft. **A**, Coronal maximum intensity projection of two-dimensional time-of-flight MR angiogram of pelvis. Focal signal loss is present in right external iliac artery (*arrow*) below distal anastomosis. Patient had normal right femoral pulse; signal loss was initially believed to be most likely caused by surgical clips. **B**, Conventional contrast angiogram of pelvis reveals patent right external iliac artery (*arrow*). No surgical clips are around vessel to explain signal loss. **C**, Coronal spoiled gradient-recalled scout image obtained at time of MR angiogram. Air-filled bowel (*arrow*) in right lower quadrant caused susceptibility artifact.

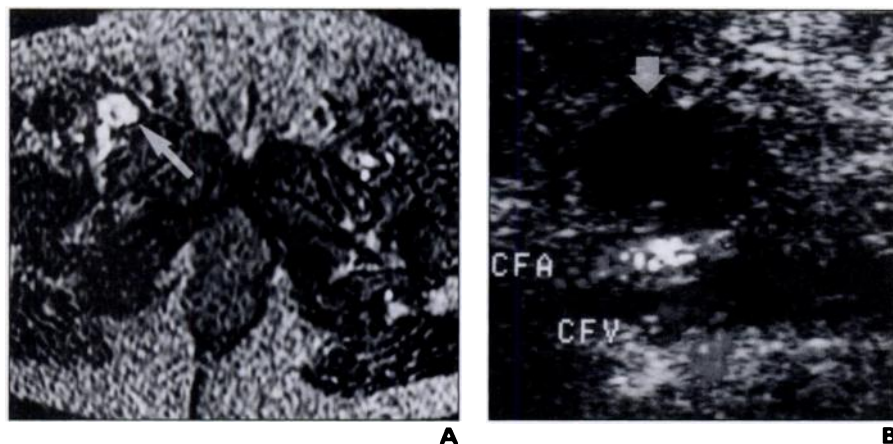


Fig. 11.—Bright signal from hematoma on two-dimensional time-of-flight MR angiogram of 61-year-old woman who underwent coronary angiography 2 days before MR angiography. **A**, Axial source image slice from MR angiogram reveals high-signal-intensity collection anterior to femoral vessels on right (arrow, site of arterial puncture), which could represent either pseudoaneurysm or hematoma. **B**, Absence of flow in collection (arrow) on color-flow duplex scan obtained immediately after MR angiogram is consistent with hematoma.

sity-projection (MIP) process, which does not distinguish between faint vascular signal and background signal [3]. Strategies to overcome this problem include examination of the axial images, cardiac gating, segmented acquisitions, and contrast enhancement [4, 5].

Signal loss also occurs when flow is turbulent, such as distal to stenoses and bifurcations, or within aneurysms (Fig. 2). Because of complex flow in these areas, the velocities (and thus phases of the spins) of blood vary greatly from voxel to voxel, which results in loss of vascular signal (in-

travoxel phase dispersion) [5]. This phenomenon contributes to the overestimation of the severity of stenoses that is typical of unenhanced MR angiography. MIP algorithms intensify the apparent signal loss by ignoring the faint signal in these vessel segments [6]. In questionable cases, gadolinium-enhanced three-dimensional MR angiography is useful because it is not susceptible to intravoxel phase dispersion [2].

A tracking inferior saturation band is necessary in 2D TOF MR angiography of the lower extremities to eliminate unwanted signal from the veins. However, if arterial flow passes through the saturation band before entering the imaging slice, it will also become saturated. This problem is common in the pelvis, where the iliac arteries can be quite tortuous. Peripheral artery occlusions may appear longer on 2D TOF MR angiography than with conventional angiography because retrograde flow in collateral vessels or the reconstituted vessel itself may be saturated by the inferior saturation band (Fig. 3).

Arterial flow in normal peripheral vessels is characteristically triphasic with a brief period of retrograde flow in early diastole [7]. Therefore, the tracking inferior saturation band is usually placed 20 mm below the imaging slice to suppress venous signal but not signal from arterial flow. Occasionally, slow venous flow remains visible when the saturation band is placed at this distance because of recovery of longitudinal magnetization by the venous spins before they enter the imaging slice [8]. In this situation we repeat the sequences with the saturation gap reduced to 5 mm (Fig. 4).

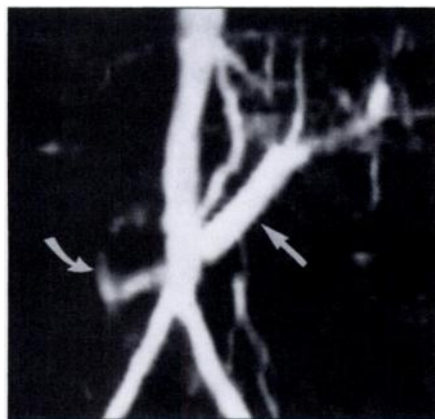

Fig. 12.—Visualization of retrograde venous flow in two-dimensional time-of-flight MR angiogram of 62-year-old man with claudication. Coronal maximum intensity projection shows large vascular structure (straight arrow) crossing distal aorta. Structure is retroaortic left renal vein (confirmed on axial source images). Flow in vein is seen because flow is craniocaudal (same direction as aorta); therefore, signal is not suppressed by inferior tracking saturation band. After vein joins inferior vena cava, flow becomes caudocranial, and signal is saturated (curved arrow).

Flow distal to stenoses is frequently brighter and the vessels appear larger than in corresponding normal vessels (Fig. 5). First-order flow compensation corrects optimally for flow at a constant velocity such as that seen distal to occlusive disease. Normal pulsatile flow is subject to signal loss because of variability in the velocity and acceleration of blood during the cardiac cycle. As a result, vessels that appear to have poor signal intensity may be normal; correlation with physical examination and noninvasive studies is essential. Cardiac gating with imaging during diastole will minimize this artifact but increases the length of the examination [5].

Pulsatile flow can cause ghosting artifacts in the phase-encoding direction. The wide range of velocities that occurs in pulsatile flow induces phase variations in addition to the phase (spatial) encoding that results in multiple images of the same vessel (Fig. 6). An important technical point in lower extremity 2D TOF MR angiography is to orient the phase encoding in the anteroposterior direction. If severe ghosting artifacts are seen, the best MIP reprojection will be the direct anterior (coronal) view because the artifact will be invisible from this perspective. Cardiac gating, smaller flip angles, or careful image postprocessing can reduce this artifact.

Patient positioning during MR angiography requires the same care as during conventional angiography. Lack of overlap between imaging stations may result in failure to diagnose a focal stenosis (Fig. 7).

Knowledge of prior vascular surgery is essential for correct performance and interpretation of MR angiography in postoperative patients. Grafts may be located in places that normally do not contain major run-off arteries, such as cross-femoral or axillofemoral grafts. These so-called extraanatomic grafts may require careful application of additional sequences to be imaged completely. Similarly, flow may be reversed in certain vessels as a consequence of a bypass procedure (Fig. 8). Gadolinium-enhanced three-dimensional MR angiography is useful in these situations.

Variation degrees of signal loss can be caused by ferromagnetic vascular clips, joint prostheses, or foreign bodies (Fig. 9). Signal loss due to metal artifact cannot be reliably detected on MIP images. Patient history plus inspection of the 2D TOF source images and radiographs are required. Signal loss due to susceptibility artifact also can occur at tissue-gas interfaces such as when bowel loops overlie an iliac artery (Fig. 10). Review of the axial slices and the localizer images may

MR Angiography of the Lower Extremities

identify this artifact as the cause of unexpected signal loss.

Not all bright signal in 2D TOF MR angiography represents flow. Substances with short T1 relaxation times also appear brighter than the background because they are not as readily suppressed by the repeated RF pulses. Signal from recent hemorrhage may be difficult to distinguish from the weak sig-

nal of flow within an aneurysm (Fig. 11). Another imaging procedure may be required to make this distinction.

Unexpected normal vascular variants and pathologic conditions may be identified on MR angiograms. Venous structures that normally contain flow in a direction opposite to the inferior vena cava, such as a retroaortic left renal vein (Fig. 12), are not suppressed

by the inferior saturation band. Venous structures containing pathologically reversed flow, such as inferior epigastric veins in portal hypertension, also may be visualized.

Patient motion during MR imaging can seriously degrade the quality of source and MIP images (Fig. 13). Background signal is increased and vascular signal is decreased. Motion artifact can simulate the appearance of signal loss from a stenosis on MIP images if the motion occurs during acquisition of a single slice. Examination of the source image may identify the artifact, but repetition of the acquisition may be necessary for adequate evaluation of the vessels.

MR angiographic techniques image flow rather than the structure of vessels. As with conventional angiography, the size of aneurysms can be greatly underestimated if chronic mural thrombus fills the sac and maintains the lumen at a nearly normal diameter (Fig. 14). Inspection of the source slices is necessary whenever aneurysmal disease is suspected.

Two-dimensional TOF MR angiography is a powerful technique for vascular imaging of the lower extremity arteries but is not without potential pitfalls and artifacts.

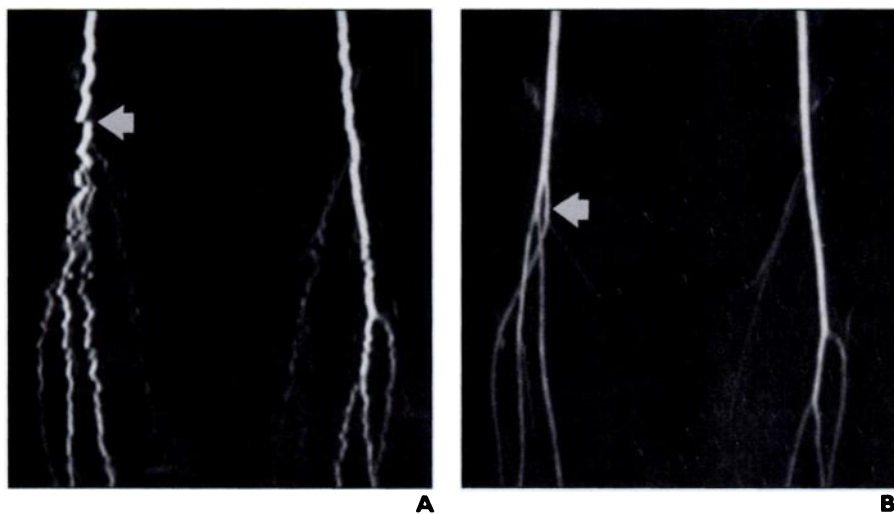


Fig. 13.—Motion artifact in two-dimensional time-of-flight MR angiogram of 14-year-old boy with suspected popliteal artery entrapment.

A, Coronal maximum intensity projection of MR angiogram of popliteal arteries during stress maneuver shows jagged vessel contours (*arrow*) due to motion and areas of increased signal intensity in background tissues. Study was uninterpretable, even with review of source images.

B, Coronal maximum intensity projection of same sequence as in **A** with careful padding of legs to prevent motion during stress maneuver shows normal popliteal arteries (high anterior tibial artery origin on right [*arrow*] is normal variant).

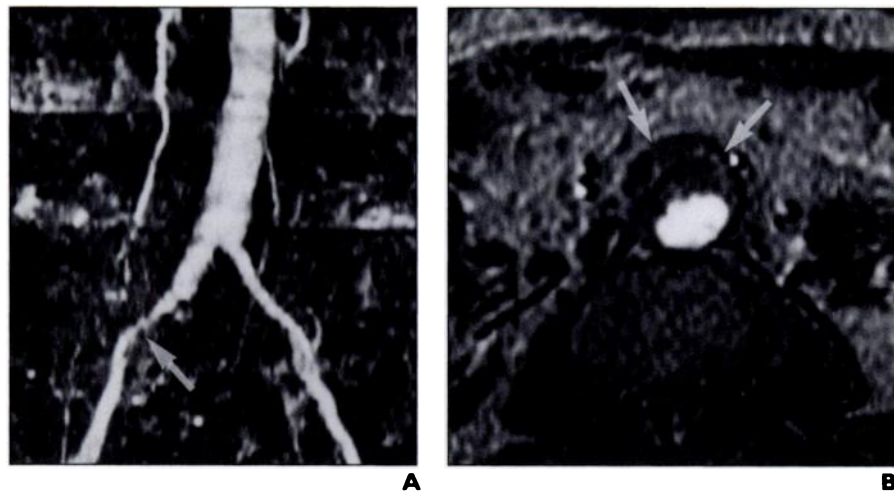


Fig. 14.—75-year-old man with claudication and unsuspected abdominal aortic aneurysm.

A, Coronal maximum intensity projection of two-dimensional time-of-flight MR angiogram of aorta and pelvis reveals slight ectasia of aorta (2 cm in diameter) and moderate right common iliac artery stenosis (*arrow*).

B, Axial slice from two-dimensional time-of-flight MR angiogram reveals presence of 4-cm abdominal aortic aneurysm (*arrows*) lined with mural thrombus. Evaluation of source images is key to avoid missing important vascular abnormalities.

References

1. Baum RA, Rutter CM, Sunshine JM, et al. Multi-center trial to evaluate vascular magnetic resonance angiography of the lower extremity. *JAMA* 1995; 274:875-880
2. Prince MR, Yucel EK, Kaufman JA, et al. Dynamic Gd-DTPA enhanced three dimensional abdominal MR angiography. *J Magn Reson Imaging* 1993; 3:877-881
3. Anderson CM, Saloner D, Tsuruda JS, Shapeero LG, Lee RE. Artifacts in maximum-intensity-projection display of MR angiograms. *AJR* 1990; 154:623-629
4. Mistretta CA. Relative characteristics of MR angiography and competing vascular imaging modalities. *J Magn Reson Imaging* 1993;3:685-698
5. Yucel EK, Silver MS, Carter AP. MR angiography of normal pelvic arteries: comparison of signal intensity and contrast-to-noise ratio for three different inflow techniques. *AJR* 1994;163:197-201
6. Anderson CM, Lee RE, Levin DL, Alonso ST, Saloner D. Measurement of internal carotid artery stenosis from source MR angiograms. *Radiology* 1994;193:219-226
7. Zierler RE, Strandness DE Jr. Nonimaging physiologic tests for assessment of extremity arterial disease. In: Zweibel WJ, ed. *Introduction to vascular ultrasonography*. 3rd ed. Philadelphia: Saunders, 1992:201-222
8. Swan JS, Kennel TW, Wojtowycz MM, Grist TM. Increased presaturation pulse gaps in two-dimensional time-of-flight MR angiography: a pitfall in diseased lower extremities. *J Vasc Interv Radiol* 1993;4:569-571