

# Update on Preoperative Breast Localization



Mary K. Hayes, MD

## KEYWORDS

- Malignant neoplasm • Breast • Wire localization (WL, WNL)
- Radioactive seed localization (RSL) • SCOUT RADAR • MAGSEED • Wire-free localization
- Targeted axillary dissection (TAD) • Radiofrequency identification (RFID)

## KEY POINTS

- Preoperative same-day wire localization (WL) using mammography, ultrasound, MR imaging, and computed tomographic (CT) guidance aids surgical excision of nonpalpable breast lesions.
- Non-wire localization devices (I125 RSL, SCOUT RADAR, MAGSEED, and RFID) may provide an alternative means to mark and aids surgical excision of nonpalpable breast lesions and axillary lymph nodes up to 5 to 30 days preoperatively under mammography, ultrasound, and CT guidance.
- Non-wire deployment systems via MR guidance are not yet available; non-wire nonradioactive devices are MR conditional.
- Non-wire devices have potential for longer-term preoperative localization in patients who undergo neoadjuvant breast cancer treatment.

 Video content accompanies this article at <http://www.radiologic.theclinics.com>.

Breast-conserving surgery is a safe and effective method to treat early breast cancer ([Video 1](#)).<sup>1-7</sup> A successful breast-conserving treatment program requires multidisciplinary communication and planning between the surgeon, radiologist, and other specialists. The goal is to safely remove the target tissue with adequate surgical margins (SM), avoid unnecessary resection of healthy breast tissue, and provide a good cosmetic outcome without compromising survival. This article reviews image-guided tools for preoperative breast/axillary node localization, and the radiologist's role in the multidisciplinary breast care team.

## CURRENT PROCEDURES

Conservative breast surgical treatment programs rely on image guidance devices and skills of

the radiologist and surgeon. **Table 1** summarizes various localization methods reviewed by Corsi and colleagues.<sup>8</sup> They reported that because no single localization tool or technique proved better for achieving adequate SM, when advantages and disadvantages of each were taken into account, each multidisciplinary surgical team should adopt the most effective localization and margin assessment technique based on the skills and technologies available. Since then, additional non-wire preoperative localization devices were US Food and Drug Administration (FDA) cleared. These non-wire devices have noninferior breast cancer surgical outcomes compared with wires.<sup>9-13</sup> In the United States, preoperative wire needle localization (WL) and non-wire localization are accepted standard methods to guide intraoperative surgical excision of nonpalpable breast lesions.

---

Disclosure Statement: The author's hospital received research support from Hologic, Inc (IRB MH#2012.048 and MH#2014.036). The author's employer receives research support from Cianna Medical (IRB MH#2016.078). The author has served on a scientific advisory panel for Hologic and Cianna Medical.

Women's Imaging, Radiology Associates of Hollywood, Sheridan-Envision, Department of Radiology, Memorial Healthcare System, 3rd Floor, 3501 Johnson Street, Hollywood, FL 33021, USA

E-mail address: [mhayes@mhs.net](mailto:mhayes@mhs.net)

Radiol Clin N Am 55 (2017) 591-603

<http://dx.doi.org/10.1016/j.rcl.2016.12.012>

0033-8389/17/© 2017 Elsevier Inc. All rights reserved.

**Table 1**  
**Summary of various localization methods**

Localization Technique	Clear Margin Rate	Disadvantages
WL	71%–87%	Wire dislodgment, vasovagal episodes, pneumothorax
Carbon marking	81%	Foreign-body reactions that may mimic malignancy
Radio-guided occult lesion localization	75%–94%	Expense, need for nuclear medicine laboratory, intraoperative tools for surgeons, intraductal injection of 99 Technetium disperses radiotracer
Clip marker localization	90%–92%	Clip migration and need for surgeon training
Hematoma ultrasound guided localization (HUG)	89%–97%	Need for surgeon training, DCIS rarely seen unless visible by clip marker or hematoma
Clip marker localization	90%–92%	Clip migration and need for surgeon training
HUG	89%–97%	Need for surgeon training, DCIS rarely seen unless visible by clip marker or hematoma
Cavity shave	91%–94%	Longer operative times; margin assessment tools needed
RSL	Noninferior to WL	Stringent nuclear regulatory rules on access, monitoring, storage, transportation, and disposal of I125 seeds

Concurrent developments in 2014 to 2016 in techniques with breast radiology non-wire localization tools for nonpalpable breast and axillary lymph nodes, as well as the updated definitions of adequate breast surgery margins from the American Society of Breast Surgeons, each offer improved ways to optimize re-excision rates, mastectomy rates, and cosmetic outcomes for patients with breast cancer.<sup>12–15</sup> The 10 tools reported by the American Society of Breast Surgeons multidisciplinary consensus panel to minimize adverse surgical outcomes of increased mastectomy rates and poor cosmetic outcomes are listed in **Box 1**.

### **Preoperative Image-Guided Localization Procedure**

Regardless of the imaging guidance method or specific needle wire/non-wire device used, all localization procedures share specific preprocedure and postprocedure steps.

#### **Preprocedure review**

Preprocedure review of the imaging and pathology reports and any clip placed during the diagnostic biopsy should be completed. Placement of a biopsy tissue marker clip (CLIP) is routine for image-guided breast biopsies and is mandated when a lesion is mammographically occult, when a lesion is difficult to visualize on post-biopsy imaging, and when it is necessary to confirm that the proper lesion has been sampled. Clip placement is useful when neoadjuvant chemotherapy

is contemplated and to correlate findings with other imaging modalities.<sup>16,17</sup>

The reviewer should assess the original extent of disease compared with the visible residual disease and the accuracy of biopsy clip placement at the target lesion. The preoperative localization target may be residual breast disease, biopsy clip, or post-biopsy hematoma. The radiologist should determine the best image-guidance method, the localization device, and coordinate any additional relevant schedules such as the operating room (OR) start time and lymphoscintigraphy injection.

#### **Postprocedure, preoperative communication**

Postprocedure, preoperative communication between the radiologist and the surgeon optimizes care. Common communication involves annotation of the images. A supplementary telephone call may be needed based on the surgeon's preference and patient details that may influence their approach. When feasible, marking the skin directly over the nonpalpable breast lesion and noting the skin-to-lesion depth with the patient in the supine operative position, can aid the surgeon.

#### **Postprocedure, intraoperative communication**

Postprocedure, intraoperative communication of the specimen radiograph findings should be expedited. Noncompression, 2-view specimen radiograph confirms the removal of the target lesion and can provide some information regarding the surgical excision and margins.<sup>16</sup> Tumor

**Box 1****Ten tools to minimize adverse surgical outcomes of increased mastectomy rates and poor cosmetic outcomes**

1. Preoperative diagnostic imaging should include full-field digital mammography and supplementary imaging to include ultrasound as needed.
2. Minimally invasive breast biopsy for breast cancer diagnosis.
3. Multidisciplinary discussions to include radiology, pathology, surgery, and radiation and medical oncology.
4. Localization of nonpalpable breast lesions via RSL, intraoperative ultrasound, or wire localization to direct lesion excision.
5. Oncoplastic techniques can reduce the need for reoperation in anatomically suitable patients.
6. Specimen orientation of 3 or more margins.
7. Specimen radiograph with surgeon intraoperative review.
8. Consider cavity shave margins in patients with T2 or greater tumor size or T1 with extensive intraductal carcinoma.
9. Intraoperative pathology assessment of lumpectomy margins may help decrease re-excisions when feasible.
10. Compliance with the SSO-ASTRO margin guideline to not routinely reoperate for close margins with “No Tumor on Ink” in patients with invasive cancer.

calcifications extending to the margins on the specimen radiograph are likely to correlate with residual tumor in the breast. Ultrasound of the specimen may be useful if the target lesion is mammographically occult but seen on ultrasound. A specimen radiograph may be used to document excision of the target CLIP for lesions that are visible only at MR imaging and preoperatively marked with a biopsy CLIP (**Fig. 1**).

Timely review and communication of specimen imaging findings directly to the surgeon impact the surgeon's decision whether to remove additional tissue. If the procedure radiologist is not available to review the specimen radiograph, a second radiologist should review the relevant needle biopsy results and radiology images to provide timely and accurate communication to the surgeon. The need for a second radiologist may occur more often when a non-wire localization device is placed 5 to 30 days before surgery.

**Postprocedure assessment of radiology-pathology concordance and communication**

Postprocedure assessment of radiology-pathology concordance and communication is the final step of preoperative localization. The radiologist performs the radiology-pathology concordance assessment, issues a final radiology report with follow-up recommendations, and confirms receipt of the final report. The treating breast surgeon issues all final results and recommendations directly to the patient in order to provide a single clear uniform postoperative treatment plan.

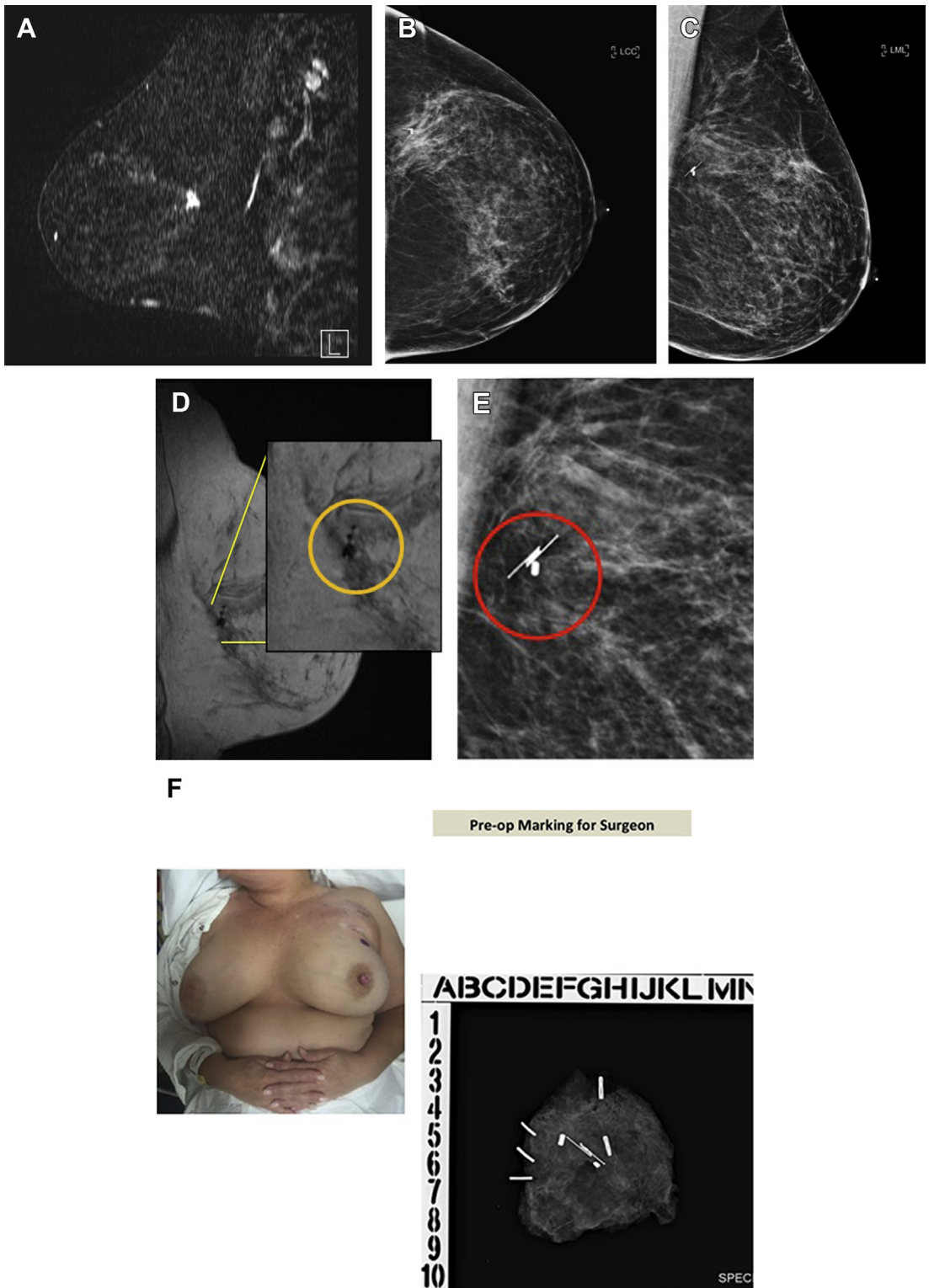
**Localization Devices: Wire Needle Localization**

Surgical excision of nonpalpable breast lesions using preoperative image-guided WL has been a cost-effective standard of care to assist surgical excision of nonpalpable breast cancer for several decades in the United States. Clear margins obtained with wire-guided excision are reported to be 70.8% to 87.4%.<sup>8,18–22</sup> Wires may be placed using mammography or ultrasound, and less commonly computed tomographic (CT) or MR guidance. Preoperative wires are placed on the same day of breast surgery and usually in the same building where surgery is scheduled. Multiple wires may be used to bracket lesions that measure 2 cm or greater or for satellite lesions.

Needle wire systems are packaged as a single-use sterilized wire. The semirigid localization wire is preloaded in a 3- to 15-cm length, 16- to 20-g needle introducer. The distal end of the semirigid localization wire varies by manufacturer and may include a barb, hook, or pigtail to anchor the wire at the intended target. The wire system is deployed when targeting is confirmed with needle/wire system at or adjacent to the target on imaging.<sup>16,23</sup> Once deployed, some wires may not be retracted, repositioned, or cut; such devices must be surgically removed.

Most often, the radiologist selects the image guidance modality used for imaging-guided WL based on the lesion visibility and patient's body habitus. Surgeons choose the wire system and communicate a preference whether the WL introducer needle should remain in place or be removed with only the wire left in place to mark the index lesion. The patient is transferred to the operating area with either the wire/needle system or the wire only. Because the wire must remain in position between the time of deployment and surgical excision, the WL requires patient compliance.

Various complications of the WL can adversely impact surgical success. Careful deployment of the WL parallel to the chest wall, securing the wire tail to the skin and minimizing breast



**Fig. 1.** A 50-year-old asymptomatic patient with mammographic and sonographic occult invasive ductal carcinoma (IDC) who presented with a 13-mm suspicious enhancing mass in the left breast (A). Stereotactically guided nonwire localization postprocedure mammogram confirms accurate deployment of the SCOUT at the bar clip in craniocaudal (CC) (B) and mediolateral (ML) (C) view. Sagittal MR with photographic enlargement of MR signal void (yellow circle in D) compares well with photographic enlargement of ML mammogram (red circle in E). T1-weighted non-fat-saturated MR image was acquired in the prone position and mammogram was acquired in the upright position. Photograph of patient in the supine operative position with skin marked over the lesion (F) can be saved to electronic chart. Specimen radiograph may be used to document excision of the target CLIP for lesions that are visible only at MR imaging and preoperatively marked with a biopsy CLIP.

movement, and shortest transit time to the OR can protect against unintended WL complications.<sup>23</sup> Because the wire should be placed immediately before surgery, logistical problems between the surgeon and radiology schedule can cause delays in surgical start time. In addition to the WL complication of wire migration, pneumothorax, site-specific pain, retention of wire fragments, hematoma, hemorrhage, bleeding, infection, adjacent tissue injury, hemoptysis, hemothorax, non-target tissue excision, organ or vessel perforation, and breast implant puncture can occur. Although wire migration typically involves locations within the breast, wire migration external to the breast (pericardium, pleural spaces, lung, mediastinum, neck muscles, axilla, and abdominal cavity) have also been reported.<sup>23–25</sup>

Retained wire fragments may occur if the wire is transected during surgery. Standard WL procedure specimen radiography provides documentation of excision of the entire wire. If the entire wire is not verified as expected, then the radiologist must notify the surgeon to search for and retrieve the missing wire fragments. Intraoperative radiograph imaging or postoperative chest CT or mammography may be needed. Rare cases of wire migration into the pleura or pericardium require thorascopic or open surgery to excise the retained wire fragment.<sup>26</sup>

The *mammographic* approach is performed under mild breast compression. The patient is commonly seated or standing upright but can also be positioned in the lateral recumbent or prone position. Mammographic guidance with 2-dimensional, stereotactic, or 3-dimensional (3D) imaging can be used. Stereotactic or 3D imaging aids in targeting lesions that are sonographically occult and can be imaged in one only mammographic projection; examples include high axillary tail lesions, including lymph nodes. Additional mammograms may be used to adjust needle wire placement.

The *sonographic* approach is performed with no breast compression. The patient is placed in the supine or supine oblique position, with the ipsilateral arm raised above the head. Ultrasound is performed using a high-frequency linear array transducer. The needle wire system is introduced at a skin entry site that is both nearest the lesion and allows a needle trajectory parallel to the chest wall. The transducer is oriented parallel to the needle trajectory for best visualization of wire deployment under real-time visualization.

The *CT* approach is performed using no breast compression with the patient in a supine or supine oblique position, with the ipsilateral arm raised above the head. A CT biopsy grid or fiducial marker on the skin provides a reference to determine the

depth and trajectory angle for WL. After the needle wire is introduced, additional limited CT images may be obtained to direct needle wire adjustments.

The *MR* approach is performed using gentle breast immobilization. The patient is placed in the prone or prone oblique position with the patient's ipsilateral arm extended above the head. MR-guided wire localization for surgical excision is uncommon and is reserved for suspicious findings visible only at MR imaging.<sup>23</sup> All equipment/supplies used in the MR suite must be MR compatible. MR WL systems are MR conditional and can be scanned safely in a static magnetic field of 3-T or less and a spatial gradient field of 720 G/cm. MR breast biopsy coils with grid and pillar-post systems are placed at the planned lateral and/or medial approach site. A skin marker or fiducial serves as a reference for measuring the depth for needle wire lesion localization.

Gadolinium contrast intravenous bolus 0.1 mmol/kg with a 10- to 20-mL saline flush is followed by an abridged contrast-enhanced MR breast imaging protocol (localizer sequence, T1, T2, 2 time point postcontrast series, and a post-procedure T1 image to confirm accurate wire placement). This short protocol balances the competing demands of rapid acquisition of high-resolution images to offset the rapid contrast washout of some suspicious lesions. Computer-aided detection software may facilitate identification and targeting of the lesion. Simultaneous bilateral imaging can be performed for bilateral breast lesions. After the needle wire is introduced, any potential additional images for adjustment of needle/wire can result in contrast material washout and limit a visibility of the lesion. In addition, artifact from the localization wire may obscure the target. Therefore, a carefully planned approach that expedites efficiency will also optimize accuracy.

### **Localization Devices: Non-wire Localization**

Although WL can be performed under mammographic, ultrasound, CT, or MR imaging guidance, none of the non-wire systems can be deployed under MR guidance at this time. Non-wire localization systems address some of the limitations of WL.<sup>9–13,27,28</sup>

**Box 2** outlines some advantages of non-wire devices. The non-wire alternative devices use send-receive technology at a specific wavelength in the electromagnetic spectrum (**Fig. 2**), ranging from high frequency–high energy to low frequency–low energy: radioactive seed localization (RSL),<sup>27–32</sup> infrared radar (SCOUT),<sup>9–11</sup> magnetic susceptometry (MAGSEED),<sup>12</sup> and radiofrequency identification (RFID).<sup>13</sup>

**Box 2****Advantages of non-wire devices over wire-guided localization**

- Avoids dislodged or migrated wires
- Flexible surgery schedules for on time start in the operating room
- Improves surgical options for cosmetic approach
- Advance placement decouples the radiology-surgery schedules
- Radiologist localization access is independent of the preferred surgical approach
- Continuous intraoperative reorientation with target centering in the specimen
- Access for TAD

Each non-wire system has 3 components: a single-use sterilized 5- to 12-mm-long device preloaded in a 12- to 18-g needle introducer, a reusable small console, and a dedicated handheld intraoperative probe (Fig. 3). The vendor may package the dedicated probe as a single-use sterilized probe or as a reusable probe with an appropriate sterile cover. Probes can detect the tag up to 4- to 6-cm depth, and the console emits real-time audio and numeric feedback to guide the surgeon during the excisional breast procedure.

Non-wire devices cannot be repositioned once deployed. More than one device may be used to bracket the full extent of disease in patients with large masses, satellite nodules, or extensive microcalcifications. Bracketing in the anterior-posterior plane is not advised because superimposed devices may be detected as only one device in the intraoperative supine patient. Marking the skin overlying the target lesion with the patient in the

supine operative position and communicating skin-to-lesion depth can aid the surgeon during excision. Postlocalization preoperative orthogonal mammography is performed (Fig. 4).

In contrast to WL procedures that are scheduled with same-day surgery, the non-wire systems can be placed 5 to 30 days before surgery. This uncoupling of the radiology and surgery schedules allows for a more flexible, efficient, on-time procedure start in the OR. This flexibility enhances scheduling options for the patient, surgeon, radiologist, and OR teams.

**Box 3** summarizes the common steps following localization with a non-wire device.

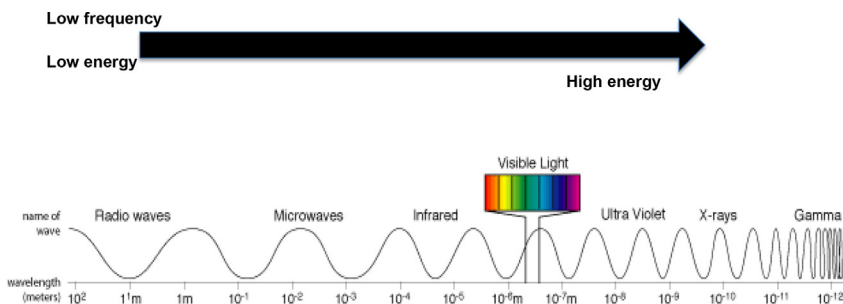
The radiologist who performs the localization procedure should prepare to interpret the specimen radiograph when possible. Because non-wire systems can be placed several days before surgery, or in a different facility, it is helpful to maintain an operative calendar for localization patients. In a multihospital setting, a shared localization calendar alert reminds the primary radiologist or alternate radiologist to review the patient imaging record and prepare for communication to the surgeon. Specimen radiographic image should be annotated to include direct OR contact number to facilitate timely communication between the radiologist and surgeon (see Fig. 4).

## TYPES OF NON-WIRE DEVICES

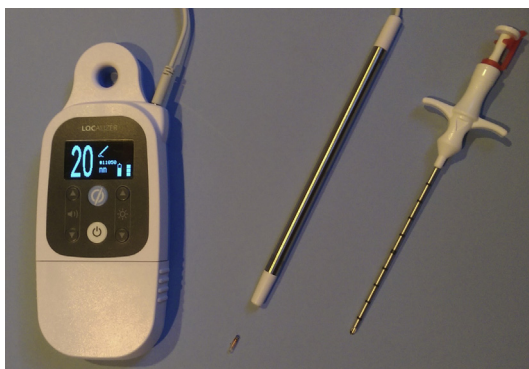Types of non-wire devices are compared in Fig. 5.

### Radioactive Non-wire Device

The radioactive non-wire devices are active and contain an energy source. Radioactive device systems are constrained by nuclear regulatory rules for radioactive devices and therefore cannot be deployed in one facility and removed in another facility.



**Fig. 2.** Electromagnetic wavelength spectrum of radiology imaging tools.



**Fig. 3.** Non-wire systems have 3 components: a single-use sterilized device preloaded in a needle introducer, a reusable console, and a dedicated handheld intraoperative probe. (Courtesy of Health Beacons, Inc, Concord, MA; with permission.)

### Radioactive I125 Seed Localization

Since Gray and colleagues<sup>27</sup> first described RSL as an alternative to needle localization in 2001, dozens of peer-reviewed articles have compared RSL with WL<sup>28–31</sup> and reported noninferior breast cancer surgical outcomes including SM, re-excision and reoperation rates, specimen size, and cosmesis.

RSL is a 5-mm I125 pellet with a titanium shell. I125 has a 60-day half-life. Because radioactivity is low (0.100–0.200 mCi [3.7–7.4 MBq]), no special instructions need to be given to the patient, family, or the public when radioactive seeds are in place.<sup>28</sup>

Deployment of RSL procedure is similar to biopsy clip placement and can be performed 0 to 5 days before surgery. The surgeon uses an intraoperative gamma ( $\gamma$ ) probe to identify and excise the target area and seed.

McGhan and colleagues<sup>29</sup> reviewed 1148 consecutive RSL procedures and reported 86% were localized with one seed with 76% placed 1 or more days before surgery. Pathologically negative margin rate was 97% of patients with invasive or in situ carcinoma (ductal carcinoma in situ, DCIS) at the first operation. Re-excision was performed in 9% of patients with invasive carcinoma and 19% of patients with DCIS for close ( $\leq 2$  mm) margins. Reported adverse events included 3 seeds (0.3%) not deployed correctly on first attempt and 30 seeds (2.6%) displaced from the breast specimen during surgical excision of the target lesion. All seeds were retrieved, with no radiation safety concerns.

Because a sentinel lymph node biopsy using technetium-99m and RSL excision can use the

intraoperative  $\gamma$  probe, both procedures can be performed at the same surgery, using the appropriate  $\gamma$ -probe settings (I125 seed emits 27 keV; technetium-99m emits 140 keV). Shin and colleagues<sup>14</sup> reported that targeted axillary dissection (TAD), selective removal of lymph nodes that were biopsy proven to contain metastasis and marked with a CLIP, may more accurately stage the axillary lymph nodes. TAD can be performed using RSL supplementary to SNL as a same-day breast or axillary surgical procedure.

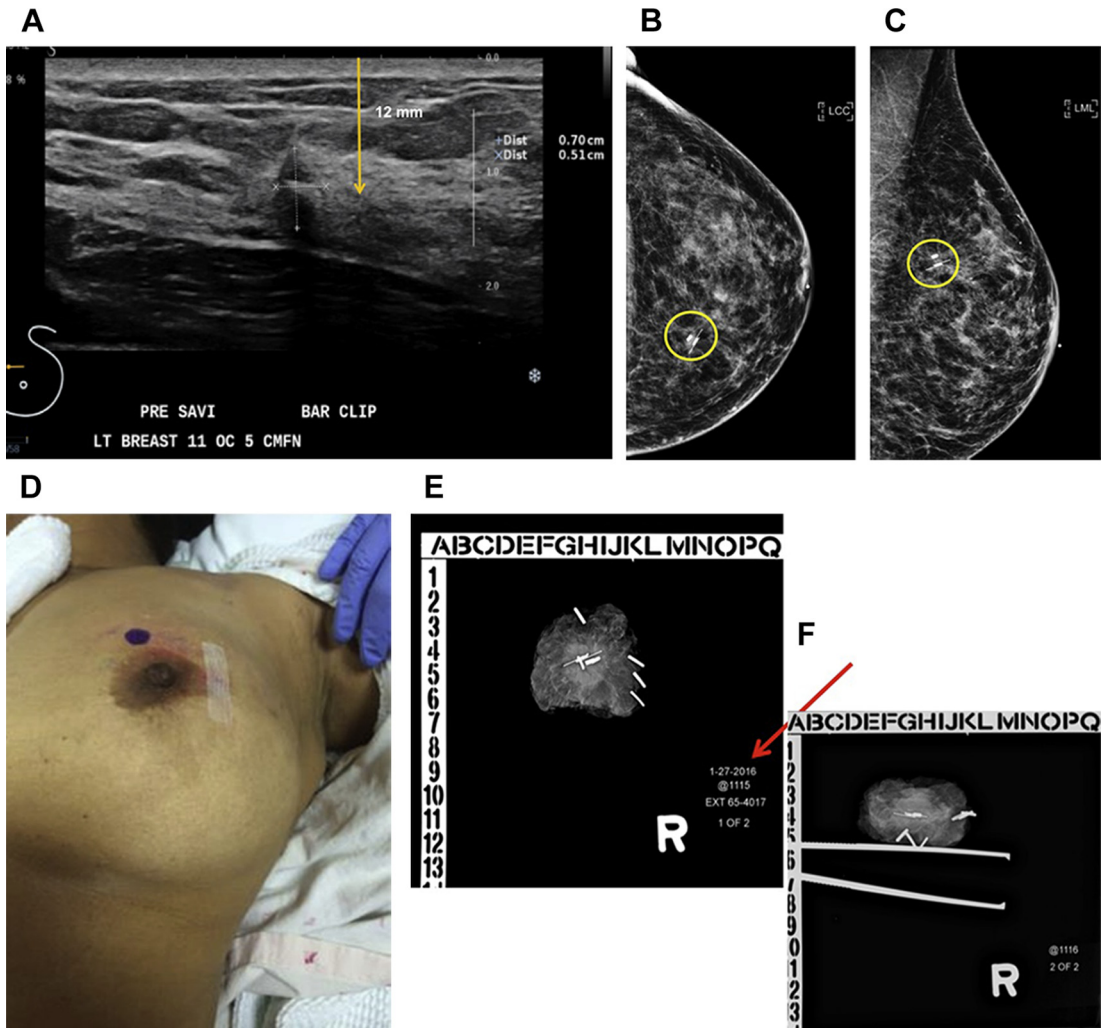
### Radioactive I125 Seed Localization Policies

A Nuclear Regulatory Commission (NRC) state license for medical use of radioactive materials is required for any facility that uses RSL. An authorized user at the facility must meet special training and experience requirements and be responsible for the safe use of radioactive material, compliance with all regulations, reporting adverse events, and ensuring staff education in radiation safety. Surgeons, pathologists, and nonauthorized radiologists implanting the seed sources work under the supervision of the authorized user and must complete approved safety training.

As such, the acquisition, implantation, excision, storage, transportation, and disposal of seeds must all fall under the same radioactive materials facility license (for radiology, surgery, pathology). The radioactive seed must be removed from the excised specimen before transport; otherwise, the Department of Transportation rules are invoked. The inventory of radioactive sources must be accounted for at all times and secured from unauthorized access or removal. Procedures must reflect location of the I125 source at any time. Loss, mishandling, or damage of a single I125 seed is reportable to the NRC.

Because the RSL gamma probe to detect extruded RSL seeds is not MR compatible, patients may not undergo MR imaging examination while the seed is in place. Lack of MRI compatibility may limit theoretic long-term RSL use for patients with breast cancer who have MR follow-up imaging in the neoadjuvant setting.

Because it is easy to learn and has noninferior surgical outcomes compared with WL, RSL is considered by some as the method of choice for localization of nonpalpable breast lesions. However, the use of radioactivity and its associated NRC safety precautions limited the widespread adoption of RSL.<sup>9–11</sup> Other nonradioactive, non-wire devices have recently become commercially available in Europe and the United States.



**Fig. 4.** Ultrasound-guided non-wire localization. Left breast ultrasound with 12-mm skin to lesion measurement (yellow arrow, A). Postlocalization, preoperative mammogram with SCOUT and CLIP yellow circles in CC (B) and ML (C) view. Photograph of the patient in the supine operative position with skin marked over the lesion (D) can be saved to electronic chart. Right breast specimen radiograph images of a separate patient are obtained in orthogonal projections and annotated to include direct OR contact number (red arrow) to facilitate timely communication between the radiologist and surgeon (E, F). Radiology-pathology concordance confirmed left IDC 5 × 7 × 5 mm, clear margins with both BAR CLIP + SCOUT in specimen.

### NONRADIOACTIVE NON-WIRE DEVICES: SCOUT, MAGSEED, AND RFID

The nonradioactive non-wire devices are passive and contain no energy source. Nonradioactive device systems are not constrained by regulations for radioactive devices and therefore can be deployed in one facility and removed in another facility.

#### SCOUT RADAR DEVICE

SCOUT is a nonradioactive non-wire localization device that uses infrared light and radar

technology. SCOUT was FDA cleared in August 2014 for localization of breast lesions. As of September 2016, SCOUT Radar has been used in more than 5000 patients in more than 75 US facilities.

The 12-mm SCOUT device is deployed via a 16-g needle introduced under imaging guidance 0 to 30 days before surgery. Retracting the release button, rather than pushing forward, to unsheathe the SCOUT, deploys the device.

The surgeon uses a dedicated intraoperative probe that emits infrared light to identify and excise the target area and SCOUT. SCOUT placed



**Box 3****Checklist of steps for non-wire device from postlocalization to postoperative report**

Checklist postdeployment of non-wire localization procedure:

- Technologist includes all biopsy clips, and devices are included on preoperative final images
- Patient is placed in the supine or supine operative position and skin is marked
- Patient photograph with skin marking can be saved to electronic medical record to aid surgeon
- Patient discharged with instructions that include contact phone numbers and marking pen to maintain skin marking
- Shared preoperative non-wire calendar includes planned surgical facility and date

Checklist for day of surgery:

- Radiologist alerted to review preoperative patient imaging record
- OR technologist obtains specimen radiograph and notifies the radiologist
- Technologist annotates specimen radiograph images with direct OR contact number
- Radiologist communicates imaging results directly to surgeon

deeper than 4.5 cm may not produce a detectable signal through the skin. When the patient is in the supine surgical position, most lesions are within target depth (**Figs. 6 and 7, Video 1**).

Cox and colleagues<sup>9,10</sup> published the initial pilot study results of 50 patients and results from the prospective multicenter study of 153 patients (11 centers, 20 radiologists, and 16 surgeons). Successful surgery in 153/153 patients, successful device placement in 99.4%, and an overall 15.8% re-excision rate were reported.

In a separate feasibility study, Mango and colleagues<sup>11</sup> reported on a single-institution retrospective study that included one breast surgeon with 15/15 successful image-guided SCOUT placements in 13 patients. Final pathology of all (10 benign and 5 malignant) lesions had clear SMs with no re-excision or complications. Successful SCOUT device placement as measured on postprocedure mammogram averaged 0.2 cm (range, 0–1.0 cm) target-to-reflector distance, similar to RSL mean target-to-seed distance of 0.1 cm (range, 0–2.0 cm).<sup>28,29</sup> One significant SCOUT migration occurred in a postbiopsy hematoma. Hematoma may also limit infrared light

transmission and subsequent detection of SCOUT.

Because the SCOUT device is passive and has no significant MR compatibility or signal void artifact limitations, the patient may safely undergo MR (at 3 T or less) with the SCOUT in place. Since there is no inherent risk of reflector expiration in 30 days, theoretically the device could be placed longer term before surgery, before neoadjuvant chemotherapy response (see **Fig. 1; Fig. 8**).

The SCOUT system costs more than WL or RSL. The one-time initial purchase of the non-wire device system console and probe contributes to the cost. An institutional cost analysis may be helpful to assess the cost comparison of WL, RSL, and SCOUT. Non-wire devices have fewer OR start delays and cancellations; nonradioactive devices have lower administrative costs because there is no RSL NRC oversight needed. A non-wire nonradioactive method to localize and excise nonpalpable breast lesions may overcome many of the WL- and RSL-related limitations.

### MAGSEED DEVICE

The MAGSEED device was FDA 510(k) cleared in March 2016 for the localization of breast lesions up to 30 days before surgery. Nonresearch, clinical use of MAGSEED has been commercially available in the US since August 2016. Two clinical studies are ongoing, one for lesion localization (NCT03020888) and one for localization of axillary lymph nodes (NCT03038152). MAGSEED is a metal marker which contains iron particles. The dedicated Sentimag probe uses MAGSEED to generate an alternating magnetic field that transiently magnetizes the iron in the MAGSEED. The tiny magnetic signature generated by MAGSEED is detected by the Sentimag probe (**Fig. 9**).

The MAGSEED device is 5 mm in length and is deployed under mammogram, ultrasound, or CT guidance. Deployment is similar to biopsy CLIP or RSL through a preloaded sterile 18-g needle introducer. MAGSEED may not produce a detectable signal through the skin if placed greater than 4.0-cm depth. MAGSEED is MR conditional at 1.5 T and 3 T<sup>12</sup>; however, 4 to 6-cm signal void artifact due to the iron content (see **Fig. 8**) may limit diagnostic accuracy of breast MR imaging when MAGSEED is in place. Finally, non-magnetic tools (eg, titanium or polymer) need to be used with Sentimag while the probe is in use. Stainless steel surgical instruments, such as metal surgical retractors may not be compatible with MAGSEED. This may add separate per use fees in addition to the initial start-up OR supply costs for the dedicated console and probe.

	DEVICE (12–18 g)	WIRE	SEED	SAVI SCOUT	MAGSEED	RFID
DEVICE SIZE	3-15 CM	5 MM	12 MM	5 MM	9 MM	
Hospital	<input checked="" type="checkbox"/>	<input checked="" type="checkbox"/>	<input checked="" type="checkbox"/>	<input checked="" type="checkbox"/>	<input checked="" type="checkbox"/>	<input checked="" type="checkbox"/>
2nd Hospital or Outpatient Center		-	<input checked="" type="checkbox"/>	<input checked="" type="checkbox"/>	<input checked="" type="checkbox"/>	<input checked="" type="checkbox"/>
same day	<input checked="" type="checkbox"/>	<input checked="" type="checkbox"/>	<input checked="" type="checkbox"/>	<input checked="" type="checkbox"/>	<input checked="" type="checkbox"/>	<input checked="" type="checkbox"/>
0–5 d	-	<input checked="" type="checkbox"/>	<input checked="" type="checkbox"/>	<input checked="" type="checkbox"/>	<input checked="" type="checkbox"/>	<input checked="" type="checkbox"/>
0–30 d	-	-	<input checked="" type="checkbox"/>	<input checked="" type="checkbox"/>	<input checked="" type="checkbox"/>	<input checked="" type="checkbox"/>
Deploy in US, MG, CT	<input checked="" type="checkbox"/>	<input checked="" type="checkbox"/>	<input checked="" type="checkbox"/>	<input checked="" type="checkbox"/>	<input checked="" type="checkbox"/>	<input checked="" type="checkbox"/>
Deploy in MRI	<input checked="" type="checkbox"/>	-	-	-	-	-
MRI Conditional	<input checked="" type="checkbox"/>	-	<input checked="" type="checkbox"/>	<input checked="" type="checkbox"/>	<input checked="" type="checkbox"/>	<input checked="" type="checkbox"/>
REPOSITION AFTER DEPLOYMENT	<input checked="" type="checkbox"/>	-	-	-	-	-
SIGNAL DEPTH	<input checked="" type="checkbox"/>	<input checked="" type="checkbox"/>	4.5 CM	4 CM	6 CM	
BRACKET	<input checked="" type="checkbox"/>	<input checked="" type="checkbox"/>	<input checked="" type="checkbox"/>	<input checked="" type="checkbox"/>	<input checked="" type="checkbox"/>	<input checked="" type="checkbox"/>
U.S. TRIALS PUBLISHED	>30 Y	2001	2014	NONE	2014	
AVAILABLE IN US	>30 Y	2001	2015	2016	Pending	

Fig. 5. Comparison of WL and non-wire localization devices.

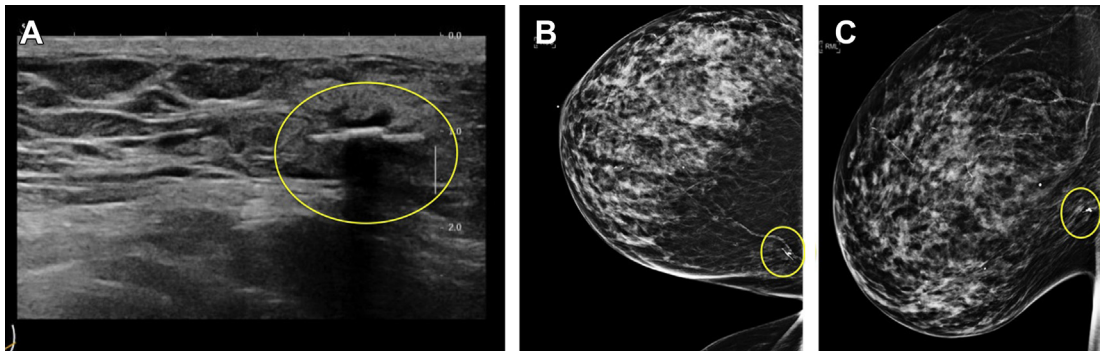
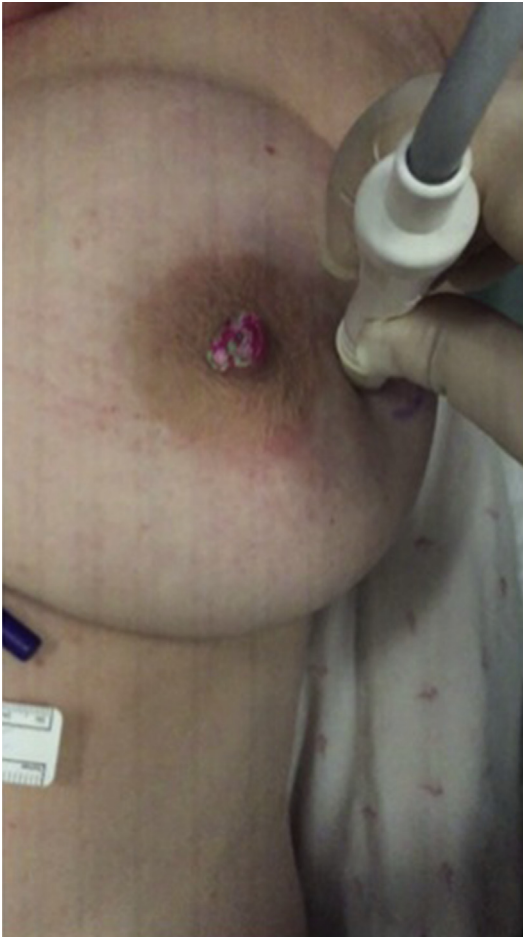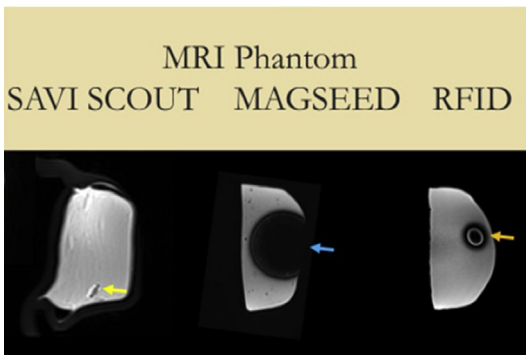



Fig. 6. IDC in posterior depth right breast at the 3:00 o'clock location would be difficult to localize with WL. Ultrasound localization documents non-wire SCOUT in the center of a hypoechoic mass with irregular margins (yellow circle A). Postlocalization mammogram confirms the posterior depth right at the 3:00 position (yellow circles) in the CC (B) and ML (C) view. This area would be difficult to localize with WL. Radiology-pathology concordance confirmed excision of a 14-mm IDC with clear margins. Receptors: estrogen receptor (ER) 100%; progesterone receptor (PR) 20%; and Her2 receptor negative.



**Fig. 7.** Patient with non-wire localization. Photograph or video clip with audio that documents the skin marking over the lesion and probe angle with optimum audio signal can aid the surgeon.



**Fig. 8.** MR images of a one-breast phantom with 3 non-wire devices. SCOUT (yellow arrow), MAGSEED (blue arrow), RFID (orange arrow) show varied signal void artifacts in noncontrast T1 non-fat-saturated MR sequences.



**Fig. 9.** Sentimag probe generates an alternating magnetic field to transiently magnetize the iron-containing MAGSEED. This signal is then detected by the Sentimag probe. (Courtesy of Endomag, Inc, Cambridge, United Kingdom; with permission.)

### RADIOFREQUENCY IDENTIFICATION TAG

The FDA has approved implantation of radiofrequency tags in humans for the purposes of identification. RFID systems use radio waves to transfer information. A passive tag has no energy source and can communicate a range of information from one serial number to several pages of data. Pending FDA clearance, the 9-mm RFID tag can be deployed 0 to 30 days before surgery through a preloaded sterile 12-g needle similar to biopsy CLIP or RSL (see Fig. 3). When the patient is in the supine surgical position, the tag can be detected within 6 cm depth of the handheld loop probe at the skin surgance and 4 cm depth of the intraoperative surgical dedicated pencil probe.<sup>13</sup>

The RFID tag contains a ferrite rod wrapped with copper and a microprocessor. The RFID device is MR conditional. However, the ferrous and copper material in RFID creates a 2-cm signal void artifact that may limit diagnostic accuracy of breast MR imaging when the RFID is in place (see Fig. 8).

The FDA is not aware of any adverse events associated with RFID. The tags have a long history of use similar to those embedded in livestock and pets as a form of identification. FDA clearance is pending for intraoperative use of the RFID intraoperative pencil probe system. Clinical nonresearch use in the US breast patients is expected in 2017.

### FUTURE OPPORTUNITIES

Future opportunities for non-wire, nonradioactive localization devices require large-scale multi-institutional studies in the United States. Areas for investigation and development may include the following:

- Longer-term placement in patients undergoing neoadjuvant treatment

- Placement in suspicious axillary lymph nodes
- MR-compatible needle introducers
- Comprehensive cost-analysis comparison to include device cost, start-up costs, institutional cost of OR delays and cancellations, administrative costs of NRC regulations

Patients who require neoadjuvant therapy, with suspicious axillary or intramammary lymph nodes, or those with lesions visible only with MR imaging could benefit from more accurate and cost-effective single-appointment localization. Streamlined single appointment could both mark the extent of disease and localize the surgical target before chemotherapeutic response.

Because non-wire device technology continues to evolve, the FDA monitors potential adverse events. Non-wire device transmitters could potentially cause interference or degrade the function of other implanted electronic medical devices, such as pacemakers, implantable defibrillators, and other electronic medical devices.

## SUMMARY

The radiologist plays an important role in detection, diagnosis, localization, pathologic correlation, and follow-up management of patients with breast cancer. The preoperative breast localization devices used by the radiologist and the refined definitions of negative SMS impact the multidisciplinary treatment of breast cancer. This article has reviewed the wire and non-wire tools available for image-guided preoperative localization. Non-wire devices provide the benefits of improved efficiency with noninferior surgical results. Preoperative lesion localization up to 30 days before scheduled surgery may lead to other longer-term efficient and cost-effective applications for patients who require neoadjuvant treatment, patients who have suspicious lymph nodes for TAD, and those with lesions visible only at MR imaging.<sup>32</sup>

## SUPPLEMENTARY DATA

Supplementary data related to this article can be found at <http://dx.doi.org/10.1016/j.rcl.2016.12.012>.

## REFERENCES

1. Singletary S. Surgical margins in patients with early stage breast cancer treated with breast conservation therapy. *Am J Surg* 2002;184:383–93.
2. Fisher E, Anderson S, Redmond C, et al. Ipsilateral breast tumor recurrence and survival following lumpectomy and irradiation: pathological findings from NSABP protocol B-06. *Semin Surg Oncol* 1992;8:161–6.
3. Fisher B, Anderson S, Bryant J, et al. Twenty-year follow-up of a randomized trial comparing total mastectomy, lumpectomy, and lumpectomy plus irradiation for the treatment of invasive breast cancer. *N Engl J Med* 2002;347:1233–41.
4. Veronesi U, Cascinelli N, Mariani L, et al. Twenty-year follow-up of a randomized study comparing breast-conserving surgery with radical mastectomy for early breast cancer. *N Engl J Med* 2002;347:1227–32.
5. Houssami N, Macaskill P, Marinovichet ML, et al. Meta-analysis of the impact of surgical margins on local recurrence in women with early-stage invasive breast cancer treated with breast-conserving therapy. *Eur J Cancer* 2010;46:3219–32.
6. Morrow M, Harris JR, Schnitt SJ. Surgical margins in lumpectomy for breast cancer—bigger is not better. *N Engl J Med* 2012;367:79–82.
7. Fisher B, Dignam J, Bryant J, et al. Five versus more than five years of tamoxifen therapy for breast cancer patients with negative lymph nodes and estrogen receptor-positive tumors. *J Natl Cancer Inst* 1996;88:1529–42.
8. Corsi F, Sorrentino L, Bossi D, et al. Preoperative localization and surgical margins in conservative breast surgery. *Int J Surg Oncol* 2013;2013:793819.
9. Cox CE, Garcia-Henriquez N, Glancy MJ, et al. Pilot study of a new nonradioactive surgical guidance technology for locating non-palpable breast lesions. *Ann Surg Oncol* 2016;23(6):1824–30.
10. Cox CE, Russel S, Prowler V, et al. A prospective, single arm, multi-site clinical evaluation of a nonradioactive surgical guidance technology for the location of nonpalpable breast lesions during excision. *Ann Surg Oncol* 2016;23(10):3168–74.
11. Mango V, Ha R, Gomberawalla A, et al. Evaluation of SAVI SCOUT surgical guidance system for localization and excision of nonpalpable breast lesions: a feasibility study. *AJR Am J Roentgenol* 2016;W1–4. <http://dx.doi.org/10.2214/AJR.15.15962>.
12. Magseed Indications for Use. Available at: [http://us.endomag.com/sites/default/files/Magseed%20IFU\\_006USA\\_v40.pdf](http://us.endomag.com/sites/default/files/Magseed%20IFU_006USA_v40.pdf). Accessed November 23, 2016.
13. Dauphine C, Reicher JJ, Reicher MA, et al. A prospective clinical study to evaluate the safety and performance of wireless localization of nonpalpable breast lesions using radiofrequency identification technology. *AJR Am J Roentgenol* 2015;204(6):W720–3.
14. Shin K, Caudle A, Kuerer HM, et al. Clinical Perspective. Radiologic mapping for targeted axillary dissection: needle biopsy to excision. *AJR Am J Roentgenol* 2016;207:1372–9.
15. Landercasper J, Attai D, Atisha D, et al. Toolbox to reduce lumpectomy reoperations and improve cosmetic outcome in breast cancer patients: The American Society of Breast Surgeons Consensus Conference. *Ann Surg Oncol* 2015;22:3174–83.

16. American College of Radiology. ACR practice parameter for the imaging management of DCIS and invasive breast carcinoma. 2013; Available at: [https://www.acr.org/~/media/ACR/Documents/PGTS/guidelines/DCIS\\_Invasive\\_Breast\\_Carcinoma.pdf](https://www.acr.org/~/media/ACR/Documents/PGTS/guidelines/DCIS_Invasive_Breast_Carcinoma.pdf). Accessed November 1, 2016.
17. Hayes M. National Consortium of Breast Centers. Poster presentation 2015; Available at: [https://www.researchgate.net/publication/281243161\\_Breast\\_Biopsy\\_Marker\\_Placement\\_Accuracy.pdf](https://www.researchgate.net/publication/281243161_Breast_Biopsy_Marker_Placement_Accuracy.pdf). Accessed November 1, 2016.
18. Homer MJ, Pile-Spellman ER. Needle localization of occult breast lesions with a curved-end retractable wire: technique and pitfalls. *Radiology* 1986;161:547–8.
19. Kopans DB, Swann CA. Preoperative imaging-guided needle placement and localization of clinically occult breast lesions. *AJR Am J Roentgenol* 1989;152:1–9.
20. Kopans DB, Meyer JE, Lindfors KK, et al. Breast sonography to guide cyst aspiration and wire localization of occult solid lesions. *AJR Am J Roentgenol* 1984;143:489–92.
21. Silverstein M, Lagios M, Groshen S, et al. The influence of margin width on local control of ductal carcinoma in situ of the breast. *N Engl J Med* 1999;340:1455–61.
22. Moy L, Newell M, Mahoney M, et al. ACR appropriateness criteria stage I breast cancer. *J Appl Commun Res* 2014;11:1160–8.
23. Mahoney M, Newell M, Bailey L, et al. ACR practice parameter for the performance of magnetic resonance imaging-guided breast interventional procedures. 2014; ACR.org/Quality-Safety Standards. Available at: [https://www.acr.org/~/media/ACR/Documents/PGTS/guidelines/MRI\\_Guided\\_Breast.pdf?la=en](https://www.acr.org/~/media/ACR/Documents/PGTS/guidelines/MRI_Guided_Breast.pdf?la=en). Accessed February 17, 2017.
24. Mahoney M, Ingram D. Breast emergencies: types, imaging features, and management. *AJR Am J Roentgenol* 1989;202:1–9.
25. Homer MJ. Transection of the localization hooked wire during breast biopsy. *AJR Am J Roentgenol* 1983;141:929–30.
26. Azoury F, Sayad P, Rizk A. Thoracoscopic management of a pericardial migration of breast biopsy localization wire. *Ann Thorac Surg* 2009;87:1937–9.
27. Gray RJ, Salud C, Nguyen K, et al. Randomized prospective evaluation of a novel technique for biopsy or lumpectomy of nonpalpable breast lesions: radioactive seed versus wire localization. *Ann Surg Oncol* 2001;8:711–5.
28. Jakub J, Gray R, Degnim A, et al. Current status of radioactive seed for localization of nonpalpable breast lesions. *Am J Surg* 2010;199(4):522–8.
29. McGhan L, McKeever S, Pockaj B, et al. Radioactive seed localization for nonpalpable breast lesions: review of 1,000 consecutive procedures at a single institution. *Ann Surg Oncol* 2011;18(11):3096–101.
30. Hughes J, Mason M, Gray R, et al. A multi-site validation trial of radioactive seed localization as an alternative to wire localization. *Breast J* 2008;14(2):153–7.
31. Sharek D, Zuley ML, Zhang JY, et al. Radioactive seed localization versus wire localization for lumpectomies: a comparison of outcomes. *AJR Am J Roentgenol* 2015;204:872–7.
32. Caudle A, Yang W, Mittendorf E. Selective surgical localization of axillary lymph nodes containing metastases in patients with breast cancer: a prospective feasibility trial. *JAMA Surg* 2015;150(2):137–43.