



In Vitro Evaluation of MR Imaging Issues at 3T for Aneurysm Clips Made from MP35N: Findings and Information Applied to 155 Additional Aneurysm Clips

BACKGROUND AND PURPOSE: Aneurysm clips need to be tested at 3T to characterize MR imaging concerns, including magnetic field interactions, MR imaging–related heating, and artifacts. Therefore, we evaluated these risks for aneurysm clips.

MATERIALS AND METHODS: Three different MP35N aneurysm clips (Codman Slim-Line Aneurysm Clip, straight, blade length 25-mm; Codman Slim-Line Aneurysm Clip Graft, 5-mm diameter × 5-mm width; Codman Slim-Line Aneurysm Clip, reinforcing 30° angle, 6-mm × 18-mm) that represented the largest mass for 155 additional clips made from MP35N were tested. The clips were evaluated at 3T for magnetic field interactions, heating, and artifacts. We studied MR imaging–related heating, placing the clip in a gelled-saline-filled phantom with MR imaging performed by using a transmit/receive radio-frequency body coil at a whole-body average SAR of 3 W/kg for 15 minutes. Artifacts were characterized by using T1-SE and GRE pulse sequences.

RESULTS: Each aneurysm clip showed relatively minor magnetic field interactions, which would not cause movement in situ. Heating was not excessive (highest temperature change, <1.8°C). Artifacts may create problems if the area of interest is in the same area or close to the aneurysm clip.

CONCLUSIONS: The results of this investigation demonstrated that it would be acceptable (ie, “MR conditional” using current terminology) for patients with these aneurysm clips to undergo MR imaging at ≤3T. Notably, on the basis of the sizes of the clips that underwent testing, these findings pertain to 155 additional aneurysm clips made from the same material.

ABBREVIATIONS: ASTM = American Society for Testing and Materials; GRE = gradient recalled-echo; MP35N = nickel-cobalt-chromium-molybdenum alloy; SAR = specific absorption rate; T1-SE = T1-weighted spin-echo

The application of a temporary or permanent vascular clip to manage an intracranial aneurysm or arteriovenous malformation is a common neurosurgical procedure.^{1,2} While the presence of a ferromagnetic aneurysm clip in an individual is a strict contraindication for an MR imaging procedure,^{3–8} aneurysm clips classified as “nonferromagnetic” or “weakly ferromagnetic” cause no known MR imaging–related problems.^{5–17}

The clinical use of 3T MR systems continues to grow, with certain advantages reported at 3T compared with lower field strength scanners.¹⁸ Biomedical implants pose possible risks and other concerns for patients referred for 3T MR imaging examinations, which include movement or displacement of the device, excessive heating of the object, and substantial artifacts, which may impact the diagnostic use of MR imaging.^{7,8} Thus, it is necessary to perform in vitro testing at 3T to characterize these MR imaging problems for implants.^{8,17,19}

This investigation assessed MR imaging risks (ie, magnetic field interactions, MR imaging–related heating, and artifacts) at 3T for 3 different aneurysm clips made from MP35N. On the basis of this material and the smaller sizes of other aneurysm clips made from MP35N, the findings of this investigation can be applied to 155 additional clips.

Materials and Methods

Aneurysm Clips

Three different aneurysm clips (Fig 1; Slim-Line Aneurysm Clip, straight, 25-mm blade length; Slim-Line Aneurysm Graft Clip, 5-mm diameter × 5-mm width; and Slim-Line Aneurysm Clip, reinforcing 30° angle, 6-mm × 18-mm; Codman & Shurtleff, a Johnson & Johnson Company, Raynham, Massachusetts) were selected for testing because they represented the largest metallic masses and sizes for 3 different versions of 155 additional aneurysm clips made from the same material, MP35N (On-line Appendix).

Magnetic Field Interactions

Each aneurysm clip was evaluated for translational attraction and torque in association with a 3T MR system (Excite active-shielded, horizontal field scanner, Software G3.0–052B; GE Healthcare, Milwaukee, Wisconsin).^{17,20–23}

Translational Attraction. To evaluate translational attraction for each aneurysm clip, the deflection-angle technique was used according to a previously described methodology.^{17,20–23} Thus, each

Received July 28, 2009; accepted after revision September 1.

From Keck School of Medicine (F.G.S.), University of Southern California and Institute for Magnetic Resonance Safety, Education, and Research, Los Angeles, California; and University of Southern California (S.V.), University Hospital, Los Angeles, California.

The work was supported by an unrestricted grant from Codman & Shurtleff, Inc, a Johnson & Johnson Company, Raynham, Massachusetts.

Please address correspondence to Frank G. Shellock, PhD, Institute for Magnetic Resonance Safety, Education, and Research, 7511 McConnell Ave, Los Angeles, CA 90045; e-mail: frank.shellock@gte.net



Indicates article with supplemental on-line tables.

DOI 10.3174/ajnr.A1918

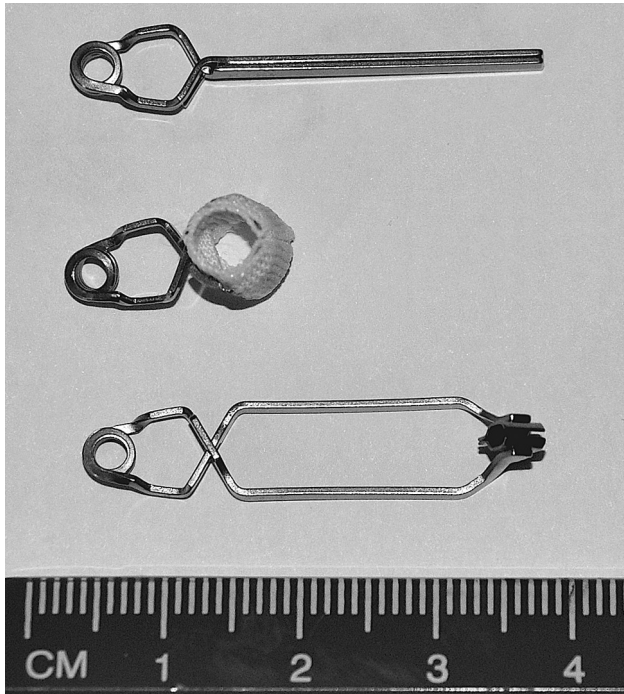


Fig 1. The aneurysm clips that underwent testing at 3T (top, Codman Slim-Line Aneurysm Clip, straight, blade length 25-mm; middle, Codman Slim-Line Aneurysm Graft Clip, 5-mm diameter \times 5-mm width; bottom, Codman Slim-Line Aneurysm Clip, reinforcing 30° angle, 6-mm \times 18-mm.

aneurysm clip was connected to a test fixture to determine the deflection angle in the 3T MR system. The test fixture incorporated a protractor with 1° graduated markings.^{17,20-23} The test sample was suspended on the apparatus by a lightweight string (20 cm in length; weight, <1% of the weight of each clip), which was fixed at the 0° indicator of the protractor. Deflection angles for each aneurysm clip were assessed at the point of the highest spatial magnetic gradient for the 3T MR system.^{17,20-23} The highest spatial magnetic gradient for the 3T scanner used in this investigation is 720 G/cm and occurs at an off-axis position 74-cm from the isocenter.²² The maximum deflection angle from the vertical direction to the nearest 1° was measured 3 times for each aneurysm clip, and an average value was calculated.^{17,20-23}

Torque. Torque for each aneurysm clip in association with exposure to the 3T MR system was determined by using a previously described qualitative assessment technique.²⁰⁻²³ This involved the use of a flat plastic device with a millimeter grid.²⁰⁻²³ Each aneurysm clip was placed on the test apparatus in an orientation that was 45° relative to the static magnetic field of the 3T MR system.²⁰⁻²³ The test apparatus was then positioned in the center of the scanner, where the effect of torque is the greatest. The clip was observed for possible alignment or rotation relative to the 3T static magnetic field. Each aneurysm clip was then moved 45° relative to its previous position and observed for alignment or rotation. This process was repeated to encompass a full 360° rotation of positions for each aneurysm clip. The following qualitative scale was applied to the results²⁰⁻²³: 0, no torque; +1, mild or low torque (the aneurysm clip slightly changed orientation but did not align to the magnetic field); +2, moderate torque (the aneurysm clip aligned gradually to the magnetic field); +3, strong torque (the aneurysm clip showed rapid and forceful alignment to the magnetic field); and +4, very strong torque (the aneurysm clip showed very rapid and very forceful alignment to the magnetic field).²⁰⁻²³

MR Imaging—Related Heating

Phantom and Experimental Setup. MR imaging—related heating at 3T/128 MHz was assessed for each aneurysm clip. This procedure used a plastic ASTM head/torso phantom filled to a depth of 10 cm with gelled saline (ie, 0.8 g/L of sodium chloride plus 5.85 g/L of polyacrylic acid in distilled water).^{20-22,24} Because this phantom and experimental setup lacked “blood flow,” it simulated an extreme condition used to assess MR imaging—related heating for the aneurysm clips.

Temperature Recording System and Placement of Thermometry Probes. Temperature measurements were obtained by using a fluoroptic thermometry system (Model 3100; LumaSense Technologies, Santa Clara, California). The Fluoroptic thermometry probes (0.5 mm in diameter) were positioned on each aneurysm clip to record representative temperatures as follows: probe 1, the sensor portion of the probe placed in contact with 1 end of the clip; probe 2, the sensor portion of the probe placed in contact with opposite end of the clip; and probe 3, the sensor portion of the probe placed in contact with middle portion of the clip. The positions of the thermometry probes were inspected and verified immediately before and after each MR imaging—related heating experiment.

MR Imaging Conditions. MR imaging was performed at 3T/128 MHz (Excite, Software G3.0–052B, GE Healthcare). The body radio-frequency coil was used to transmit and receive radio-frequency energy. MR imaging parameters were selected to generate a relatively high level of radio-frequency energy,²⁰⁻²² producing an MR imaging system—reported whole-body average SAR of 3.0 W/kg for 15 minutes. The land-marking position (ie, the center position or anatomic region for the MR imaging procedure) and section locations were selected to encompass the entire area of each aneurysm clip.

Experimental Protocol. Each aneurysm clip was placed in the ASTM head/torso phantom at a position midline on the left side, slightly (5 mm) below the mid-depth (vertical orientation) of the gelled saline. For this particular 3T/128-MHz MR imaging system and experimental setup, the left side of the ASTM head/torso phantom was found to be associated with a greater temperature rise than the right side of the head/torso phantom for a given implant or device (ie, based on pilot experiments). Therefore, each aneurysm clip was placed on the left side of the ASTM head/torso phantom to yield the worst case temperature rise for the described measurement conditions, based on prior analysis of device heating for this particular MR imaging system (ie, due to asymmetry in heating patterns for this phantom and MR imaging system).²⁵⁻²⁷

The aneurysm clip was positioned in the plastic phantom using a grid and small plastic posts technique, as previously described.²⁰⁻²² The Fluoroptic thermometry system was calibrated, and the Fluoroptic thermometry probes were applied. The phantom was filled with the gelled saline and allowed to equilibrate to the environmental temperature for more than 24 hours. The MR imaging system fan was not on during the MR imaging—related heating investigations. The room and MR imaging system bore temperatures were at constant levels throughout each experimental session. After recording baseline temperatures (5 minute), MR imaging was performed for 15 minutes with temperatures recorded at 20-second intervals. This procedure was repeated for the next aneurysm clip after the gelled saline returned to thermoequilibrium, facilitated by manual mixing and verified by recording temperatures at multiple positions in the phantom. The highest temperature changes recorded by the Fluoroptic thermometry probes are reported for each aneurysm clip. With this pro-

Table 1: Summary of magnetic field interactions at 3T for the aneurysm clips

Aneurysm Clip	Deflection Angle (Degree, Mean)	Torque (Mean)
Codman Slim-Line Aneurysm Clip, straight, 25-mm blade length	6 ± 0	0 ± 0
Codman Slim-Line Aneurysm Graft Clip, 5-mm diameter × 5-mm width	4 ± 0	0 ± 0
Codman Slim-Line Aneurysm Clip, reinforcing 30° angle, 6-mm × 18-mm	5 ± 0	0 ± 0

cedure, the MR imaging–related heating information applies to a “per-pulse sequence” aspect of the MR imaging examination.

The background temperature was also recorded in the ASTM head/torso phantom. Thus, the temperature change was recorded at the position in the phantom in association with MR imaging–related heating of the gelled-saline-filled phantom without the clip present. To record the background temperature, we placed a fluoroptic thermometry probe in the ASTM head/torso phantom at a position mid-line on the left side, slightly (5 mm) below the mid-depth (vertical orientation) of the gelled saline.

Artifacts

MR imaging artifacts were assessed at 3T for each aneurysm clip. This test was performed by MR imaging with each aneurysm clip attached to a plastic frame and then placed in a gadolinium-doped saline-filled plastic phantom.^{13,20–22,25} MR imaging was conducted by using a 3T MR system (Excite, Software G3.0–052B, GE Healthcare), a transmit/receive radio-frequency head coil, and the following pulse sequences: 1) T1-SE sequence: TR, 500 ms; TE, 20 ms; matrix size, 256 × 256; section thickness, 10 mm; FOV, 24 cm; NEX, 2; bandwidth, 16 kHz; and 2) GRE pulse sequence: TR, 100 ms; TE, 15 ms; flip angle, 30°; matrix size, 256 × 256; section thickness, 10 mm; FOV, 24 cm; NEX, 2; bandwidth, 16 kHz.

The imaging planes were oriented to encompass the long and short axes of each aneurysm clip. The frequency-encoding direction was parallel to the plane of imaging. The image locations obtained through each aneurysm clip represented the largest or worst case artifacts (ie, based on reviewing multiple section locations in each imaging plane for each clip), and these were selected for evaluation. Planimetry software was used to measure (accuracy and resolution ± 10%) the cross-sectional area of the largest artifacts size for each aneurysm clip for each pulse sequence and for each orientation of the section location.^{20–22} The image display parameters (ie, window and level settings, magnification, etc) were carefully selected and used in a consistent manner to provide valid measurements of sizes for the artifacts.^{20–22} This methodology has been used in many previous reports involving the characterization of artifacts for metallic implants.^{20–22}

Results

The average deflection angles ranged from 4° to 6° for the 3 different aneurysm clips, and the qualitatively measured torque was 0, no torque in each case (Table 1). Findings for the MR imaging–related heating assessments for the aneurysm clips indicated that the highest temperature changes were ≤1.8°C (range, 1.6°C–1.8°C; Table 2). The background temperature change was 1.6°C. Artifacts test results are presented in Table 3. In general, the artifacts associated with the 3 different aneurysm clips were seen as signal-intensity losses or “voids,” which were slightly larger than the size and shape of

Table 2: Summary of MR imaging–related heating at 3T for the aneurysm clips

Thermometry Probe	Highest Temperature Change (°C)
Codman Slim-Line Aneurysm Clip, straight, 25-mm blade length	
1	+1.7
2	+1.8
3	+1.6
Background	+1.6
Codman Slim-Line Aneurysm Graft Clip, 5-mm diameter × 5-mm width	
1	+1.6
2	+1.7
3	+1.6
Background	+1.6
Codman Slim-Line Aneurysm Clip, reinforcing 30° angle, 6-mm × 18-mm	
1	+1.7
2	+1.7
3	+1.7
Background	+1.6

each clip, with the GRE pulse sequence producing larger artifacts than the T1-SE pulse sequence. Figure 2 shows examples of artifacts for the aneurysm clips, as seen on the gradient pulse sequence in the view oriented to the long axis of the respective clip.

Discussion

Magnetic Field Interactions

The average deflection angles ranged from 4° to 6° at 3T for the aneurysm clips made from MP35N. This information should be considered in view of the information provided by the ASTM International,²³ which states: “If the implant deflects less than 45°, then the magnetically induced deflection force is less than the force on the implant due to gravity (its weight). For this condition, it is assumed that any risk imposed by the application of the magnetically induced force is no greater than any risk imposed by normal daily activity in the Earth’s gravitational field.” Therefore, the 3 different aneurysm clips that underwent testing passed this acceptance criterion with respect to exposure to the 3T MR system. The qualitatively measured torque was 0, no torque, in each case. Therefore, these aneurysm clips would not present a hazard to a patient in a 3T MR imaging environment with respect to magnetic field interactions.

For a metallic implant in the MR imaging environment, the associated magnetic field interactions are dependent on the strength of the static magnetic field, the maximum spatial gradient, the mass of the object, the shape of the object, and the magnetic susceptibility of the materials.^{5–9,11,16,19} As previously stated, the 3 different aneurysm clips were specifically selected for testing at 3T in this investigation because they represented the largest metallic masses and sizes for 3 different versions of 155 additional aneurysm clips (On-line Appendix) made from MP35N. Therefore, because these additional aneurysm clips have lower masses and dimensions, the magnetic qualities are predicted to be less, with the findings for magnetic field interactions for the 3 clips tested appropriately applied to these implants relative to the 3T MR imaging environment.

Table 3: Summary of artifacts sizes for the aneurysm clips evaluated at 3T

Clips/Feature	T1-SE	T1-SE	GRE	GRE
Codman Slim-Line Aneurysm Clip, straight; 25-blade length				
Signal-void size (mm ²)	457	222	1251	1351
Imaging plane ^a	Long axis	Short axis	Long axis	Short axis
Codman Slim-Line Aneurysm Graft Clip, 5-mm diameter × 5-mm width				
Signal-void size (mm ²)	785	608	1595	1576
Imaging plane ^a	Long axis	Short axis	Long axis	Short axis
Codman Slim-Line Aneurysm Clip, reinforcing 30° angle, 6-mm × 18-mm				
Signal-void size (mm ²)	1062	553	2240	2034
Imaging plane ^a	Long axis	Short axis	Long axis	Short axis

^a Imaging plane relative to each aneurysm clip.




Fig 2. MR imaging artifacts associated with the 3 different aneurysm clips. *A*, Codman Slim-Line Aneurysm Clip, straight, 25-mm blade length. *B*, Codman Slim-Line Aneurysm Clip Graft, 5-mm diameter × 5-mm width; *C*, Codman Slim-Line Aneurysm Clip, reinforcing 30° angle, 6-mm × 18-mm (GRE pulse sequence; TR/TE, 100/15 ms; flip angle, 30°; matrix size, 256 × 256; section thickness, 10 mm; FOV, 22 cm; long-axis imaging plane).

MR Imaging-Related Heating

Using a relatively high level of radio-frequency energy (ie, MR imaging system—reported whole-body average SAR, 3.0 W/kg) at 3T with each aneurysm clip placed in a worst case position in an unperfused phantom yielded maximum temperature changes that ranged from 1.6°C to 1.8°C. Notably, the background temperature change associated with the same experimental conditions was 1.6°C. These recorded temperature increases for the aneurysm clips are not considered to be physiologically consequential for a human subject.³⁰

Excessive MR imaging—related heating can occur in an implant,^{7,8,19,27,31} but this tends to happen in an object that has a certain length or is in the shape of a closed loop with a relatively large diameter or both.^{7,8,19,31} For an aneurysm clip, the length and closed loop aspects of the design must be considered because these factors could impact the heating characteristics of this implant. In view of the fact that aneurysm clips are fairly short and have very small closed loops (Fig 1), the associated MR imaging—related heating will not be substantially higher than the background temperature, even during extreme experimental conditions at 3T, as demonstrated by the findings of this investigation. Notably, because the 3 aneurysm clips tested had the largest dimensions (albeit relatively short) compared with those listed in On-line Appendix, the results of the MR imaging—related heating tests will pertain to these other clips, with a presumed lack of excessive temperature rises.

Artifacts

While many factors are known to affect the size of an artifact observed with a metallic implant, it is well known that for

aneurysm clips, the extent of the size is predominantly dependent on the magnetic susceptibility of the material.^{8-10,13,15,28,29}

Therefore, the associated artifacts may affect the diagnostic use of the MR imaging examination if the area of interest is the same as or close to that in the proximity of the aneurysm clip made from MP35N. Optimization of pulse-sequence parameters to minimize artifacts size is, thus, recommended.

Conclusions

In consideration of the minor magnetic field interactions, the relatively mild heating (ie, above the background temperature when using extreme experimental conditions), and characterization of artifacts, the results of this investigation demonstrated that it would be acceptable (ie, “MR conditional” using current MR imaging—labeling terminology) for patients with these aneurysm clips to undergo MR imaging procedures at 3T or less.^{32,33} Notably, in consideration of the sizes of the clips that underwent testing, these findings also pertain to 155 additional aneurysm clips made from the same material, MP35N (On-line Appendix).

References

1. Yasargil MG. *Microsurgery Applied to Neurosurgery*. Stuttgart, Germany: Georg Thieme; 1969:126–130
2. Burns JD, Brown RD Jr. **Treatment of unruptured intracranial aneurysms: surgery, coiling, or nothing?** *Curr Neurol Neurosci Rep* 2009;9:6–12
3. Klucznik RP, Carrier DA, Pyka R, et al. **Placement of a ferromagnetic intracerebral aneurysm clip in a magnetic field with a fatal outcome.** *Radiology* 1993; 187:855–56
4. Johnson GC. **Need for caution during MR imaging of patients with aneurysm clips.** *Radiology* 1993;188:287–88
5. Kanal E, Shellock FG. **MR imaging of patients with intracranial aneurysm clips.** *Radiology* 1993;187:612–14

6. Shellock FG, Kanal E. **Policies, guidelines, and recommendations for MR imaging safety and patient management.** *J Magn Reson Imaging* 1991;1:97–101
7. Shellock FG, Spinazzi A. **MRI safety update 2008. Part 2. Screening patients for MRI.** *AJR Am J Roentgenol* 2008;191:1140–49
8. Shellock FG. *Reference Manual for Magnetic Resonance Safety, Implants and Devices: 2009 Edition.* Los Angeles: Biomedical Research Publishing Group; 2009
9. New PFJ, Rosen BR, Brady TJ, et al. **Potential hazards and artifacts of ferromagnetic and nonferromagnetic surgical and dental materials and devices in nuclear magnetic resonance imaging.** *Radiology* 1983;147:139–48
10. Becker RL, Norfray JF, Teitelbaum GP, et al. **MR imaging in patients with intracranial aneurysm clips.** *AJR Am J Roentgenol* 1988;9:885–89
11. Kanal E, Shellock FG, Lewin JS. **Aneurysm clip testing for ferromagnetic properties: clip variability issues.** *Radiology* 1996;200:576–78
12. Shellock FG, Crues JV. **High-field strength MR imaging and metallic biomedical implants: an ex vivo evaluation of deflection forces.** *AJR Am J Roentgenol* 1988;151:389–92
13. Shellock FG, Shellock VJ. **Spetzler aneurysm clips: compatibility at MR imaging.** *Radiology* 1998;206:838–41
14. Shellock FG, Kanal E. **Yasargil aneurysm clips: evaluation of interactions with a 1.5 Tesla MR system.** *Radiology* 1998;207:587–91
15. Pride GL, Kowal J, Mendelsohn DB, et al. **Safety of MR scanning in patients with nonferromagnetic aneurysm clips.** *J Magn Reson Imaging* 2000;12:198–200
16. Shellock FG, Tkach JA, Ruggieri PM, et al. **Aneurysm clips: evaluation of magnetic field interactions and translational attraction using “long-bore” and “short-bore” 3.0-Tesla MR systems.** *AJNR Am J Neuroradiol* 2003;24:463–71
17. Shellock FG. **Biomedical implants and devices: assessment of magnetic field interactions with a 3.0-Tesla MR system.** *J Magn Reson Imaging* 2002;16:721–32
18. Kuhl CK, Träber F, Giesecke J, et al. **Whole-body high-field-strength (3.0-T) MR imaging in clinical practice. Part II. Technical considerations and clinical applications.** *Radiology* 2008;247:16–35
19. Woods TO. **Standards for medical devices in MRI: present and future.** *J Magn Reson Imaging* 2007;26:1186–89
20. Shellock FG, Gounis M, Wakhloo A. **Detachable coil for cerebral aneurysms: in vitro evaluation of magnet field interactions, heating, and artifacts at 3-Tesla.** *AJNR Am J Neuroradiol* 2005;26:363–66
21. Shellock FG, Wilson SF, Mauge CP. **Magnetically programmable shunt valve: MRI at 3-Tesla.** *Magn Reson Imaging* 2007;25:1116–21. Epub 2007 Jan 19
22. Shellock FG, Valencina S. **Ventricular assist implant (AB5000): in vitro assessment of MRI issues at 3-Tesla.** *J Cardiovasc Magn Resonance* 2008;10:23–28
23. American Society for Testing and Materials (ASTM. Designation: F 2052-02). **Standard test method for measurement of magnetically induced displacement force on passive implants in the magnetic resonance environment.** In: *Annual Book of ASTM Standards: Section 13—Medical Devices and Services.* Vol 13.01. West Conshohocken, Pennsylvania: Medical Devices: Emergency Medical Services; 1576–1580
24. American Society for Testing and Materials International (ASTM. Designation F 2182–02a). **Standard test method for measurement of radio frequency induced heating near passive implants during magnetic resonance imaging.** In: *Annual Book of ASTM Standards.* West Conshohocken, Pennsylvania: ASTM International
25. Amjad A, Kildishev AV, Park SM, et al. **Power deposition inside of a phantom for testing MRI heating.** *IEEE Trans Magn* 2005;41:4185–87
26. Nordbeck P, Fidler F, Weiss I, et al. **Spatial distribution of RF-induced E-fields and implant heating in MRI.** *Magn Reson Med.* 2008;60:312–91
27. Langman DA, Desphande VS, Thorsten F, et al. **Asymmetric pacemaker lead tip heating along the x-axis in 1.5-T and 3-T MR systems.** In: *Proceedings of the International Society for Magnetic Resonance in Medicine.* Berkeley, California: 2007;15:1079
28. Shellock FG, Kanal E. **Aneurysm clips: evaluation of MR imaging artifacts at 1.5-T.** *Radiology* 1998;209:563–66
29. Olsrud J, Latt J, Brockstedt S, et al. **Magnetic resonance imaging artifacts caused by aneurysm clips and shunt valves: dependence on field strength (1.5 and 3-T) and imaging parameters.** *J Magn Reson Imaging* 2005;22:433–37
30. Houdas Y, Ring EF. *Human Body Temperature: Its Measurements and Distribution.* New York: Plenum; 1982
31. Dempsey MF, Condon B, Hadley DM. **Investigation of the factors responsible for burns during MRI.** *J Magn Reson Imaging* 2001;13:627–31
32. American Society for Testing and Materials (ASTM. Designation: F2503–05). **Standard practice for marking medical devices and other items for safety in the magnetic resonance environment.** In: *Annual Book of ASTM Standards.* West Conshohocken, Pennsylvania: ASTM International; 2005
33. Shellock FG, Woods TO, Crues JV 3rd. **MRI labeling information for implants and devices: explanation of terminology.** *Radiology* 2009;253:26–30