

MRI Features of Intracerebral Hemorrhage Within 2 Hours From Symptom Onset

Italo Linfante, MD; Rafael H. Llinas, MD; Louis R. Caplan, MD; Steven Warach, MD, PhD

Background and Purpose—MRI has been increasingly used in the evaluation of acute stroke patients. However, MRI must be able to detect early hemorrhage to be the only imaging screen used before treatment such as thrombolysis. Susceptibility-weighted imaging, an echo-planar T2* sequence, can show intracerebral hemorrhage (ICH) in patients imaged between 2.5 and 5 hours from symptom onset. It is unknown whether MRI can detect ICH earlier than 2.5 hours. We describe 5 patients with ICH who had MRI between 23 and 120 minutes from symptom onset and propose diagnostic patterns of evolution of hyperacute ICH on MRI.

Methods—As part of our acute imaging protocol, all patients with acute stroke within 24 hours from symptom onset were imaged with a set of sequences that included susceptibility-weighted imaging, diffusion- and perfusion-weighted imaging, T1- and T2-weighted imaging, fluid-attenuated inversion recovery (FLAIR), and MR angiography using echo-planar techniques. Five patients with ICH had MRI between 23 and 120 minutes from the onset of symptoms.

Results—ICH was identified in all patients. Distinctive patterns of hyperacute ICH and absence of signs of ischemic stroke were the hallmark features of this diagnosis. The hyperacute hematoma appears to be composed of 3 distinct areas: (1) center: isointense to hyperintense heterogeneous signal on susceptibility-weighted and T2-weighted imaging; (2) periphery: hypointense (susceptibility effect) on susceptibility-weighted and T2-weighted imaging; and (3) rim: hypointense on T1-weighted imaging and hyperintense on T2-weighted imaging, representing vasogenic edema encasing the hematoma.

Conclusions—MRI is able to detect hyperacute ICH and show a pattern of evolution of the hematoma within 2 hours from the onset of symptoms. (*Stroke*. 1999;30:2263-2267.)

Key Words: hemoglobins ■ intracerebral hemorrhage ■ magnetic resonance imaging ■ stroke
■ tissue plasminogen activator

Noncontrast CT scan is currently the imaging modality most widely used to exclude the presence of hemorrhage in the evaluation of candidates for thrombolysis.¹ MRI by diffusion- and perfusion-weighted sequences can provide data on the pathophysiology of ischemia and potentially guide therapeutic decisions.^{1a} However, MRI must be able to reliably detect acute hemorrhage in order to be the only imaging study used before thrombolysis.

Despite traditional skepticism about the capability of MRI to detect acute hemorrhage, there is a considerable amount of data on the MR properties of hemoglobin degradation products.²⁻⁵ As blood extravasates into the tissue, the molecule of hemoglobin becomes deoxygenated. The presence of unpaired electrons makes deoxyhemoglobin a paramagnetic substance. Deoxyhemoglobin thereby produces a nonuniform magnetic field that results in rapid dephasing of proton spins in T2- and more so in T2*-weighted images.^{3,6} This property of paramagnetic molecules such as deoxyhemoglobin is termed *magnetic susceptibility effect* and results in signal loss

(darkening) best seen in images that are T2- or T2*-weighted.⁶ Echo-planar (EPI) T2*- or susceptibility-weighted imaging (SWI) was able to detect signal loss due to the presence of deoxyhemoglobin in a series of 6 patients with intracerebral hemorrhage (ICH) imaged between 2.5 and 5 hours from symptom onset.⁷ Schellinger et al⁸ reported that T2- and T2*-weighted images were as sensitive as CT in identifying ICH in 9 patients imaged from 3 to 6 hours from symptom onset. However, it is unknown whether MRI can detect ICH earlier than 2.5 hours.

We now report 5 patients with ICH who had MRI between 23 and 120 minutes from symptom onset and propose a pattern of evolution of acute ICH on MRI.

Subjects and Methods

The standard practice for patients arriving at the emergency department of Beth Israel Deaconess Medical Center within 24 hours from onset of symptoms suggestive of stroke is to obtain a routine set of MRI sequences acutely. This set includes EPI diffusion-weighted imaging (DWI), SWI, EPI fluid-attenuated inversion recovery

Received June 9, 1999; revision received July 26, 1999; accepted July 26, 1999.

From the Department of Neurology, Beth Israel Deaconess Medical Center, Boston, Mass (I.L., R.H.L., L.R.C.), and Section of Stroke Diagnostics and Therapeutics, Stroke Branch, National Institute of Neurological Disorders and Stroke, National Institutes of Health, Bethesda, Md (S.W.).

Correspondence to Italo Linfante, MD, Department of Neurology, Division of Cerebrovascular Diseases, Beth Israel Deaconess Medical Center, East Campus DA 779, Harvard Medical School, 330 Brookline Ave, Boston, MA 02115. E-mail ilinfant@caregroup.harvard.edu

© 1999 American Heart Association, Inc.

Stroke is available at <http://www.strokeaha.org>

(FLAIR), T1-weighted imaging (T1WI), T2-weighted imaging (T2WI), MR angiography (MRA), and perfusion-weighted imaging (PWI). Over the last 2-year period, the diagnosis of ICH was made in 5 patients imaged in <2.5 hours from symptom onset. The diagnosis was based on clinical and neuroimaging evaluation by the stroke fellow, the stroke attending physician, and the neuroradiologist. Investigations were ordered by the treating physician. CT scans were not routinely performed in patients who had acute MR studies. Moreover, since the present study was not a comparative study of MRI versus CT, CT scans were only obtained in 2 patients 7 and 9 hours from symptom onset (patients 1 and 3).

Data Acquisition

MRI studies were performed on a Siemens Vision 1.5 scanner (Siemens Medical System). All equipment was approved by the Food and Drug Administration for use in patients, and scans were obtained as part of the patients' routine diagnostic workup. The pulse sequences and typical parameters were as follows: (1) turbo fast low-angle shot (FLASH) T1-weighted localizer: repetition time (TR), 15 ms; echo time (TE), 6 ms; flip angle, 30°; 3 slices; 3 planes; slice thickness, 8 mm; matrix size, 128×256; field of view (FOV), 300 mm; acquisition time, 10 seconds; (2) DWI, EPI spin echo: TR, 6000 ms; TE, 99 ms; 18 slices; slice thickness, 7 mm; matrix size, 96×128; FOV, 240 mm; b value, 1000 s/mm²; acquisition time, 30 seconds; (3) SWI, EPI gradient echo: TR, 0.8 ms; TE, 60 ms; flip angle, 60°; 20 slices; slice thickness, 7 mm; matrix size, 96×128; FOV, 240; acquisition time, 2 seconds; (4) T1WI: TR, 600 ms; TE, 12; flip angle, 90°; 20 slices; slice thickness, 5 mm; matrix size, 128×256; FOV, 240; acquisition time, 46 seconds; (5) turbo spin-echo T2/proton density (T2WI): TR, 3800 ms; TE, 22/90 ms; flip angle, 180°; 20 slices; slice thickness, 5 mm; matrix size, 128×256; FOV, 240 mm; acquisition time, 1 minute and 42 seconds; (6) EPI FLAIR: TR, 0.8 ms; TE, 53 ms; flip angle, 90°; 18 slices; slice thickness, 7 mm; matrix size, 84×128; FOV, 240 mm; acquisition time, 4 seconds; and (7) PWI, EPI gradient echo: TR, 0.8 ms; TE, 47 ms; flip angle, 60°; 12 slices; slice thickness, 7 mm; matrix size, 96×128; FOV, 240; acquisition time, 40 seconds, 1 second per set (40 sets).

Patients

Patient 1 is a 66-year-old man with hypertension and thrombocytopenia secondary to cyclosporin treatment. At 1:45 AM he had acute onset of right-sided weakness and right hemisensory loss. On examination he was awake, alert, and oriented, and he responded to questions appropriately. He had slight lower face weakness and slight weakness and numbness of the right arm and hand. National Institutes of Health Stroke Scale (NIHSS) score was 4. In the emergency department at 4:40 AM, he suddenly vomited, became mute, developed left eye deviation, lower face weakness, right hemiplegia, and was difficult to arouse. NIHSS score was 22. The scan started at 5:03 AM, 23 minutes from the sudden deterioration. MRI showed a left thalamic bleed with extension to the subcortical white matter. CT obtained 9 hours after symptom onset shows a hyperdense area of the same size and location. The patient's neurological examination was unchanged when the CT was obtained.

Patient 2 is a 63-year-old man with acute onset of severe headache and left-sided weakness and numbness at approximately 5:15 PM. The patient's blood pressure was 240/160 mm Hg; he had a left homonymous hemianopia, left face weakness, left hemiplegia, and decreased sensation on the left side of his body. NIHSS score was 15. MRI was performed at 6:06 PM, 51 minutes from symptom onset. MRI showed right putaminal ICH with extension to the internal capsule and thalamus.

Patient 3 is a 48-year-old man with sudden onset of difficulty speaking and right arm, leg, and face weakness at 10:30 AM. The patient's blood pressure was 235/152 mm Hg, and heart rate was 48 bpm. He was awake and oriented, with a right face, arm, and leg hemiparesis. NIHSS score was 9. MRI was performed at 11:49 AM, 79 minutes from symptom onset. MRI showed a left thalamic ICH with extension to the internal capsule. CT obtained 7 hours after symptom onset showed a hyperdense area of the same size and

location. The patient's neurological examination was unchanged when the CT was obtained.

Patient 4 is a 36-year-old woman who had had a cesarean section 10 days previously. At 7:45 AM she fell down with slurred speech and left-sided weakness. Blood pressure was 122/58 mm Hg. She had a left facial weakness, right forced gaze, and dense left hemiplegia. NIHSS score was 15. MRI was performed at 9:26 AM, approximately 101 minutes from symptom onset. MRI showed a right putaminal ICH with extension to the internal capsule.

Patient 5 is an 87-year-old woman with hypertension who had sudden onset of dysphagia, fell down, and had decreased level of consciousness at 11:45 AM. Blood pressure was 215/150 mm Hg. She was difficult to arouse, had marked dysarthria, 1- to 2-mm poorly reactive pupils, vertical nystagmus, dysmetria, and weakness of the right face, arm, and leg. NIHSS score was 12. The scan started at 1:45 PM, 120 minutes from symptom onset. MRI showed a left pontomedullary junction ICH.

Results

The diagnosis of ICH was made by the stroke fellows (I.L., R.H.L.), the stroke attending physicians (L.R.C., S.W.), the neurology attending physician, and the neuroradiologist on the basis of risk factors, clinical findings, clinical course, and outcome. ICH was readily identified in all patients by the neuroradiologists as part of their clinical routine evaluation. The simultaneous acquisition of conventional MRI sequences (ie, T1WI, T2WI, and FLAIR) ruled out other pathologies such as abscesses, neoplastic lesions, or ischemic stroke.

The results of SWI, T1WI, T2WI, FLAIR, DWI, and CT are shown in Figure 1 for patient 1 and in Figure 2 for patient 3. The SWI results are shown for all patients chronologically in Figure 3. Characteristic patterns on MRI were best defined on SWI, T2WI, and T1WI.

The lesion can be divided into 3 parts: a center, a periphery, and a surrounding rim. The center has isointense to hyperintense signal characteristics on T2WI and SWI, which may appear heterogeneous, particularly in larger lesions (patient 4, Figure 3). The center is isointense to hypointense on T1WI and becomes smaller over time. The periphery shows an enlarging area of signal loss on SWI. This hypointense area is present to a lesser extent on T2WI and is not apparent on T1WI. A surrounding rim of hyperintensity on T2WI and to a lesser extent on SWI circumscribes the periphery of the hematoma. The surrounding rim is hypointense on T1WI. This area most likely reflects vasogenic edema surrounding the hematoma. For large lesions (eg, patient 4 in this series), the hematoma may have a marbled appearance in the center and/or the periphery. The signal loss is more homogeneous in the patient imaged at 120 minutes and is present only at the periphery of the hematoma in the patient imaged at 23 minutes.

On the basis of the history and neurological examination, we posit that patient 1 had 2 hemorrhages. The first hemorrhage most likely occurred 3 hours before the scan, when he noticed the sudden onset of slight hemiparesis. The second hemorrhage most likely occurred 23 minutes before the scan, when the patient had sudden onset of vomiting, altered consciousness, deviation of the eyes, and hemiplegia. SWI showed a 1- to 2-cm area of signal loss in the left thalamus and the basal ganglia. This area most likely represents the hematoma that was responsible for the sudden onset of mild hemiparesis and (based on the clinical presentation), that occurred approximately 3 hours before the MRI. SWI showed

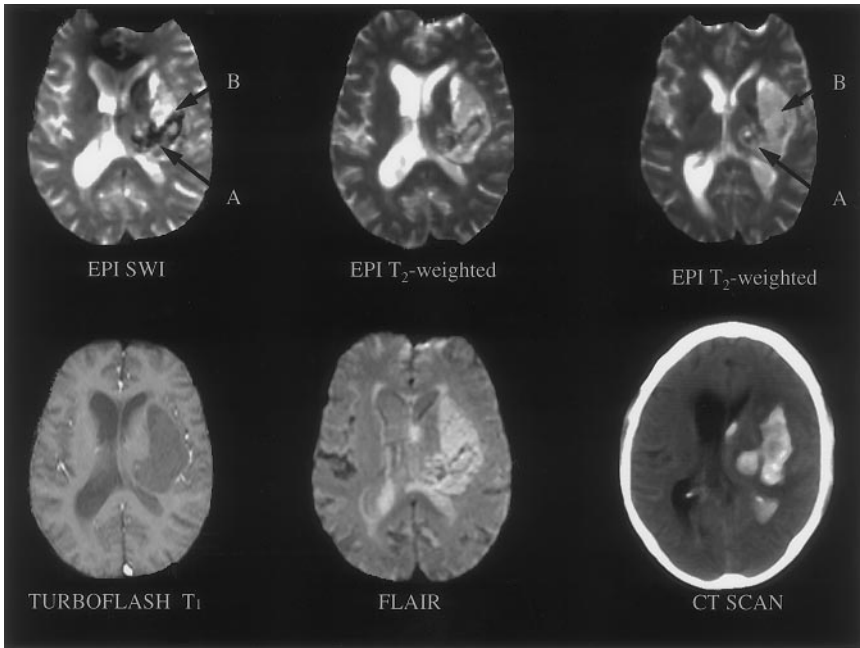


Figure 1. MRI of patient 1 obtained after 23 minutes from the acute onset of mutism, severe right hemiplegia, and unresponsiveness subsequent to a 3-hour onset of mild right-sided weakness and mild hemisensory loss. SWI shows signal loss in the left thalamus (arrow A), most likely 3 hours after symptom onset, and a larger hyperintense area extending laterally and anteriorly into the white matter causing mass effect (arrow B), that developed most likely 23 minutes after symptom onset. Two contiguous slices on EPI T2WI show a matching but less prominent area of signal loss in the left thalamus (arrow A) and a large hyperintense area extending upstream into the white matter (arrow B). TurboFLASH T1WI shows a matching homogeneous area of hypointensity (conventional T1WI was marred by motion artifact). CT obtained 9 hours from symptom onset shows the left thalamic hematoma with extension into the subcortical white matter.

another area (3 to 4 cm) that is hyperintense to white matter and hypointense to cerebrospinal fluid, with a periphery of signal loss. We posit that the hyperintensity in the center of the hematoma represents the new hemorrhage that caused sudden vomiting, loss of consciousness, and hemiplegia 23 minutes before the MRI.

Discussion

In ICH, hemoglobin passes from an environment with high oxygen concentration (arterial blood) to an environment with a lower oxygen concentration (tissue). It has been proposed that cerebral blood flow and pH are decreased in the underperfused tissue surrounding the hematoma.⁹ These alterations might promote local shift in the hemoglobin oxygenation

curve in favor of the formation of deoxyhemoglobin. Signal loss on long-TR/short-TE, long-TR/long-TE, and gradient-echo images is the earliest published change observed in a rat model of ICH.¹⁰ Such signal characteristic is present at the earliest point at which the animals were imaged, ie, 1 hour from the induction of the hematoma. In those animals, histology correlated signal loss to the transformation (within the erythrocytes) of hemoglobin to deoxyhemoglobin, starting from the most peripheral areas of the hematoma.¹⁰ In the series of Patel et al,⁷ signal loss was present on SWI, within the hematoma, as early as the patient underwent an MRI scan (eg, 2.5 hours). In agreement with these observations, SWI, in our patients, is the sequence that more clearly shows signal loss due to the presence of deoxyhemoglobin. It seems to

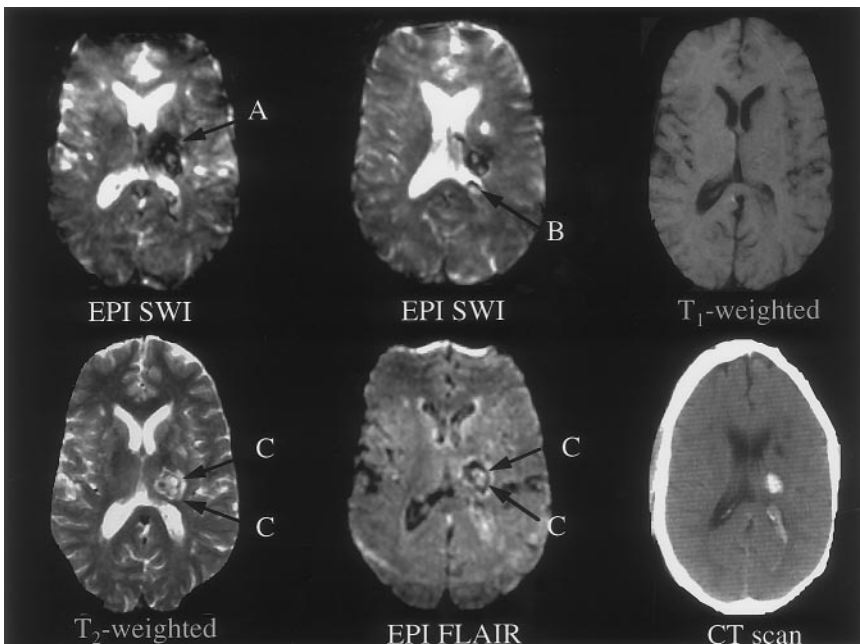


Figure 2. MRI of patient 3 obtained after 79 minutes from sudden onset of right-sided weakness and numbness. Two contiguous slices on SWI show signal loss in the left thalamus (arrow A) with extension in the posterior limb of the internal capsule and invasion of the posterior horn of the left lateral ventricle (arrow B). The small center of the lesion has increased intensity. T1WI demonstrates subtle changes in the lesion: hypointense rim and heterogeneous center. T2WI and FLAIR show the same lesion present on SWI as an area of increased signal intensity with a periphery of signal loss (arrows C) and a surrounding rim of increased signal intensity, most likely due to vasogenic edema encasing the hematoma. CT obtained 7 hours from symptom onset shows a left thalamic hematoma.

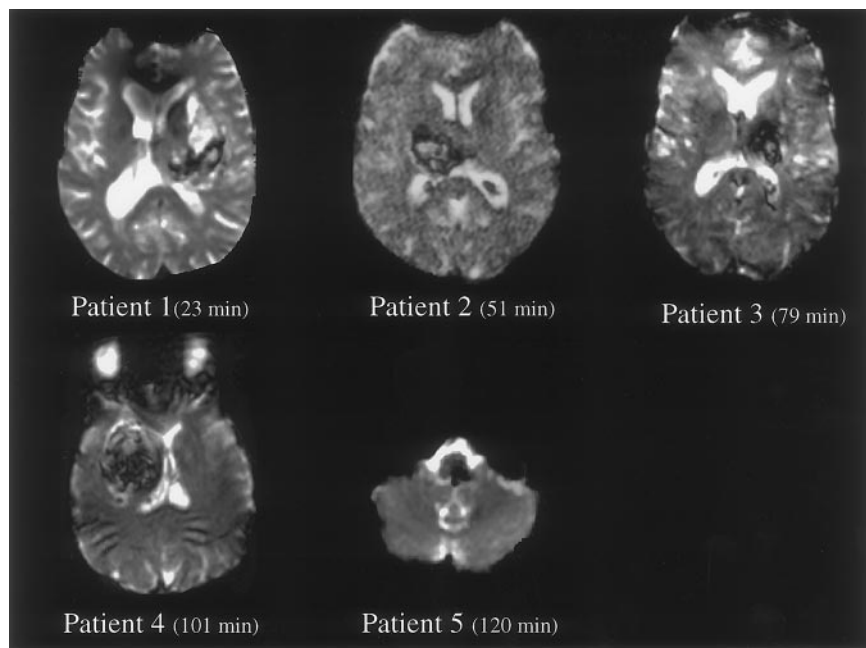


Figure 3. SWI of all 5 patients showing the pattern of temporal evolution of the signal changes in ICH. SWI shows the progressive extension of the signal loss due to the presence of deoxyhemoglobin from the periphery toward the center of the hematoma. The signal loss is present only in the periphery of the hematoma in patient 1 and is completely hypointense in patient 5.

progress from the periphery of the hematoma (Figure 3) toward the center. This observation has been described both in animal models¹⁰ and in patients with ICH.^{7,10} According to the authors, it can be explained by the presence of deoxyhemoglobin being the highest in the periphery of the hematoma.¹⁰ The meaning of the increased signal intensity seen on SWI in the center of the acute ICH is unknown. This signal intensity is higher than in normal tissue but lower than in edema or cerebrospinal fluid. We hypothesize that fresh blood in the center of a hyperacute ICH has signal characteristics of a proteinaceous solution since proton relaxation times are not yet significantly influenced by the presence of deoxyhemoglobin.^{5,12}

On the basis of our and other data, a model of ICH MRI signal characteristics from 23 minutes to 5 hours and their interpretation is summarized in the Table. The lesion appears to be made of 3 parts: a center, a periphery, and a surrounding rim. These parts evolve over time. The hyperintense center becomes progressively smaller over time, as deoxygenation of extravascular blood progresses from the periphery inward. For smaller (eg, patient 5 in this series) or later lesions, the hematoma becomes completely hypointense earlier. For larger lesions (eg, patient 4 in this series), the hematoma may have a marbled appearance at the center and periphery. In

such cases, the evolution to complete hypointensity might be slower. As shown by T2WI, the outer rim of vasogenic edema enlarges over the hyperacute period. However, on SWI the increased signal intensity due to the vasogenic edema might be overwhelmed by the signal loss because of the susceptibility effect of deoxyhemoglobin.

The increased signal intensity present on FLAIR and T2WI and the hypointensity present on T1WI are useful in ruling out ischemic stroke. In fact, these sequences would be expected to be normal within the first 2 hours after the onset of ischemia.

DWI does not seem to be as specific for hemorrhage as it is for ischemic stroke, and the diagnosis of hemorrhage should be based on other sequences. Attempts to measure the apparent diffusion coefficient in ICH are inherently flawed and systematically underestimated since any susceptibility effect will cause dephasing (ie, lower signal intensity) at all b values. Therefore, in an acute ICH, because of the susceptibility effect of deoxyhemoglobin, it would be difficult to measure correctly the apparent diffusion coefficient.

Schellinger et al⁸ measured lesion volume in patients with ICH imaged with MRI and CT between 3 and 6 hours from symptom onset. They concluded that T2WI and T2*-weighted images were as sensitive as CT in identifying ICH in the 9 patients imaged. The authors did not present data on patients

MRI Signal Features of Hyperacute Hemorrhage

	Center	Periphery	Surrounding Rim	Acute Evolution
SWI	Iso/hyperintense, heterogeneous	Hypointense	Hyperintense, hypointense at later times	Progressive enlargement of hypointense periphery toward center
T2WI	Iso/Hyperintense, heterogeneous, larger than SWI	Hypointense, smaller than SWI	Hyperintense	Slower progressive enlargement of hypointense periphery toward center
T1WI	Iso/hypointense, heterogeneous	Isointense	Hypointense	Hypointense rim enlargement
Interpretation	Oxyhemoglobin dominant	Deoxyhemoglobin dominant	Vasogenic edema	Progressive increase in concentration of deoxyhemoglobin from periphery toward center

imaged within 3 hours from symptom onset. To our knowledge, this is the first report of MRI signal changes in patients with ICH imaged between 23 and 120 minutes from symptom onset. EPI/T2*-weighted imaging (SWI) seems the most useful image modality in detecting signal changes in the hyperacute phase of ICH. By SWI, data from the entire brain are acquired in 2 seconds of total scan time (20 slices, 7 mm thick). The finding is useful because a set of MRI sequences (DWI, SWI, FLAIR, T1WI, T2WI, PWI, and MRA) can provide multiple and complementary data in a total scan time of 15 minutes. Such data could be employed in the screening and use of thrombolytic and neuroprotective agents.^{1a} In conclusion, before MRI becomes clinical routine evaluation of ICH, larger prospective investigations are needed. However, we suggest that MRI may be diagnostic in the evaluation of hyperacute ICH.

Acknowledgments

This study was supported by the National Institute of Neurological Diseases and Stroke and by the American Heart Association (Dr Warach). The authors wish to thank Mahesh Patel, MD, and the Department of Neuroradiology of Beth Israel Deaconess Medical Center for the advice in the interpretation of the MR images.

References

1. The National Institute of Neurological Disorders and Stroke rt-PA Stroke Study Group. Tissue plasminogen activator for acute ischemic stroke. *N Engl J Med*. 1995;333:1581–1587.
- 1a. Baird AE, Warach S. Magnetic resonance imaging of acute stroke. *J Cereb Blood Flow Metab*. 1998;18:583–609.
2. Hackney DB, Atlas SW, Grossman RI, Gormori JM, Goldberg HI. Subacute intracranial hemorrhage: contribution of spin density to appearance on spin-echo MR images. *Radiology*. 1987;165:199–202.
3. Atlas SW, Mark AS, Grossman RI, Gormori JM. Intracranial hemorrhage: gradient-echo MR imaging at 1.5T: comparison with spin-echo imaging and clinical applications. *Radiology*. 1988;7:193–199.
4. Hayman LA, Taber KH, Ford JJ, Bryan RN. Mechanisms of MR signal alteration by acute intracerebral blood: old concepts and new theories. *AJNR Am J Neuroradiol*. 1991;12:899–907.
5. Bradley WG Jr. MR appearance of hemorrhage in the brain. *Radiology*. 1993;189:15–26.
6. Edelman RR, Johnson K, Buxton R, Shoukimas G, Rosen BR, Davis KR, Brady TJ. MR of hemorrhage: a new approach. *AJNR Am J Neuroradiol*. 1986;7:751–756.
7. Patel MR, Edelman RR, Warach S. Detection of hyperacute primary intraparenchymal hemorrhage by magnetic resonance imaging. *Stroke*. 1996;27:2321–2324.
8. Shellinger P, Jansen O, Fiebach JB, Hacke W, Sartor S. A standardized MRI stroke protocol comparison with CT in hyperacute intracerebral hemorrhage. *Stroke*. 1999;30:765–768.
9. Nath FP, Kelly PT, Jenkins A, Mendelow AD, Graham DI, Teasdale GM. Effects of experimental intracerebral hemorrhage on blood flow, capillary permeability and histochemistry. *J Neurosurg*. 1987;66:555–562.
10. Atlas SW, Thulborn KR. MR detection of hyperacute parenchymal hemorrhage of the brain. *AJNR Am J Neuroradiol*. 1998;19:1471–1477.
11. Deleted in proof.
12. Fullerton GD. Physiologic basis of magnetic relaxation. In: Stark DD, Bradley WG, eds. *Magnetic Resonance Imaging*. 2nd ed. St Louis, Mo: Mosby Year Book; 1992:88–108.

MRI Features of Intracerebral Hemorrhage Within 2 Hours From Symptom Onset

Italo Linfante, Rafael H. Llinas, Louis R. Caplan and Steven Warach

Stroke. 1999;30:2263-2267

doi: 10.1161/01.STR.30.11.2263

Stroke is published by the American Heart Association, 7272 Greenville Avenue, Dallas, TX 75231

Copyright © 1999 American Heart Association, Inc. All rights reserved.

Print ISSN: 0039-2499. Online ISSN: 1524-4628

The online version of this article, along with updated information and services, is located on the World Wide Web at:

<http://stroke.ahajournals.org/content/30/11/2263>

Permissions: Requests for permissions to reproduce figures, tables, or portions of articles originally published in *Stroke* can be obtained via RightsLink, a service of the Copyright Clearance Center, not the Editorial Office. Once the online version of the published article for which permission is being requested is located, click Request Permissions in the middle column of the Web page under Services. Further information about this process is available in the [Permissions and Rights Question and Answer](#) document.

Reprints: Information about reprints can be found online at:
<http://www.lww.com/reprints>

Subscriptions: Information about subscribing to *Stroke* is online at:
<http://stroke.ahajournals.org/subscriptions/>