

# The Wire and Beyond: Recent Advances in Breast Imaging Preoperative Needle Localization

Megha Madhukar Kapoor, MD

Miral Mahesh Patel, MD

Marion Elizabeth Scoggins, MD

**Abbreviations:** LCC = left craniocaudal, LLM = left lateromedial, OR = operating room, RCC = right craniocaudal, RFID = radiofrequency identification, RLM = right lateromedial, RSL = radioactive seed localization

**RadioGraphics** 2019; 39:1886–1906

<https://doi.org/10.1148/rg.2019190041>

**Content Codes:**  

From the Department of Diagnostic Radiology, University of Texas MD Anderson Cancer Center, 1515 Holcombe Blvd, Unit 1350, Houston, TX 77030. Presented as an education exhibit at the 2018 RSNA Annual Meeting. Received March 3, 2019; revision requested May 1 and received May 29; accepted June 18. For this journal-based SA-CME activity, the author M.E.S. has provided disclosures (see end of article); all other authors, the editor, and the reviewers have disclosed no relevant relationships. **Address correspondence** to M.M.K. (e-mail: [mmkapoor@mdanderson.org](mailto:mmkapoor@mdanderson.org)).

©RSNA, 2019

## SA-CME LEARNING OBJECTIVES

After completing this journal-based SA-CME activity, participants will be able to:

- List known complications of wire localization procedures.
- Describe the advantages of using nonwire localization systems.
- Recognize the distinguishing features of various nonwire localization devices.

See [rsna.org/learning-center-rg](http://rsna.org/learning-center-rg).

Many patients with breast cancer are candidates for breast conservation therapy. This group includes individuals with small nonpalpable tumors detected at screening mammography and those with sufficient tumor shrinkage after neoadjuvant chemotherapy. Breast conservation surgery often requires the use of an imaging-guided preoperative localization procedure, during which a device is placed within or adjacent to the target lesion to guide the surgeon intraoperatively. For decades, wire localization has been the standard for preoperative localization in breast imaging. With this method, a wire is placed in the breast percutaneously, with the distal wire segment positioned adjacent to the abnormality and the proximal wire segment remaining outside the breast. Because of the external component of the wire, the patient must be compliant, and care must be taken to not disturb the wire's position before surgery. Scheduling flexibility is also limited because the wire localization must be performed on the same day as the subsequent surgery. More recently, the available options for performing preoperative localization have expanded greatly and now include the use of nonwire devices such as radioactive and magnetic seeds, radar reflectors, and radiofrequency identification tags. Nonwire localization devices can be placed days in advance of the surgery, at the patient's convenience, to avoid wire-related challenges and complications. They are placed percutaneously within or adjacent to the target breast lesion and detected intraoperatively by using a probe outside the breast.

©RSNA, 2019 • [radiographics.rsna.org](http://radiographics.rsna.org)

Mammographic screening of asymptomatic women is used to detect breast cancer early and has been shown to result in an absolute reduction in mortality (1). In 2018, approximately 2 million new breast cancer cases were diagnosed worldwide (2). Mammographic screening-detected malignancies are often small, clinically occult, and amenable to breast conservation therapy, as opposed to mastectomy. The aim of breast conservation therapy, a safe and effective method of breast cancer treatment, is to remove targeted tissue with adequate surgical margins while avoiding unnecessary resection of healthy tissue (3). In addition, breast conservation therapy may be appropriate for women with a larger tumor burden when neoadjuvant chemotherapy results in tumor shrinkage.

Use of wire and nonwire localization techniques can facilitate breast conservation therapy by enabling the clinician to guide surgical excision of nonpalpable breast lesions. For decades, the standard for preoperative breast lesion localization has been wire localization. In recent years, the options for nonwire localization have expanded and now include radioactive and magnetic seeds, radar reflectors, and radiofrequency identification (RFID) tags. The objectives of this article are to provide an overview of the preoperative localization

## TEACHING POINTS

- The advantages of nonwire localization techniques, as compared with wire localization, are improved scheduling flexibility, lack of a wire, potential to remove less nontarget tissue, potential for improved cosmesis, and improved access for targeted axillary node dissection.
- RSL offers all of the major advantages of nonwire localization techniques, without detection being limited by the seed's depth from skin. However, the substantial number of regulations for using nuclear materials limits the widespread adoption of this localization technique and is associated with specific challenges.
- Radar reflector localization is advantageous, as compared with RSL, because of the lack of radioactivity, lack of regulatory issues, and potential for long-term implantation of the reflector. This device is also advantageous because there are minimal artifacts at MRI. However, the reflector device should not be placed within or deep to a hematoma. In addition, because the reflector antennae contain nitinol, there is potential for an allergic reaction in patients known to be allergic to nitinol.
- A magnetic seed is the smallest nonradioactive localization device and offers advantages that are similar to those offered by other nonradioactive nonwire localization techniques. Because ferromagnetic instruments will interfere with the signal when the probe is in use, nonferromagnetic surgical instruments are necessary. However, the use of these tools may result in additional start-up costs.
- Each RFID tag's unique identification number helps to identify the tags, as the identification number will be displayed on the reader.

process, review the history of localization techniques, and describe recent advances in breast imaging localization technology.

### Historical Perspective

During the early years of screening mammography, surgical biopsy was the only way that tissue sampling of a breast abnormality could be performed. Before the advent of core-needle biopsy and needle localization techniques, a surgeon would review the mammogram and grossly estimate the location of the lesion for excision. He or she would then perform the excision, usually removing excess tissue to ensure the excised specimen contained the target lesion (4). Because a lesion identified on a mammogram often proved to be benign, critics often voiced concerns regarding the high false-positive rates of early mammographic screening programs (4). The eventual success of early screening programs was directly related to the development and use of needle localization techniques to guide surgical biopsies such that only small amounts of tissue had to be removed to establish a diagnosis (4).

In these early needle localization procedures, the radiologist would place a plain straight needle in the corresponding quadrant of the breast, as close as possible to the target lesion, to guide

the surgeon as to where to excise tissue (4). The surgeon often requested that the needle be introduced perpendicular to the chest wall, along the anticipated path of surgical dissection (5). This localization method was limited because the needle was placed by using a freehand technique and the needle could be easily displaced during mammographic compression or the transfer of the patient (5). Thus, breast imagers would tape the needle hub to the skin to prevent it from being displaced, with occasional reports of needle-induced pneumothorax (5).

In 1979, Ferris Hall and Howard Frank developed a guidewire that could be positioned in the breast. The wire had a hook on the end so that it would remain in the intended position (5). This device had limitations. The hooked wire tip protruded from the needle tip, preventing repositioning of the wire once it was inserted into the breast. The needle and wire could be advanced farther but not retracted because the hook extended beyond the needle. In addition, because the external portion of the wire protruded only slightly from the needle hub, there was the potential for wire migration into the breast (5). To address these issues, Daniel Kopans developed a spring-hook wire system that could be after-loaded into the needle. Thus, the needle could be repositioned as many times as needed before the wire was loaded and deployed (5). Kopans made the wire longer than other available wires at that time, limiting the danger of it being drawn into the breast, and added a thickened wire segment to aid the surgeon in identifying the lesion relative to the hook (4,5).

In 1983, Marc Homer created a J-shaped wire made of nitinol, a metal alloy of nickel and titanium. This wire could be reconfigured countless times while being pulled in and out of the needle, allowing accurate placement of the guidewire (5). Because the wire could not be easily palpated, Homer left the needle in place over the J-wire. Therefore, the device could be repositioned, could be more readily palpated by the surgeon, and could not be easily transected (5). Ultimately, many different needle-wire localization devices were created and used according to radiologist and surgeon preferences. For decades, physicians have successfully used needle-wire systems as effective localization tools in breast imaging.

### Preoperative Localization Process

Regardless of which localization technique is used, the overall process for performing preoperative breast imaging lesion localization is the same (Fig 1). Before the procedure, the radiologist reviews the relevant imaging and histopathologic findings to become familiar with the

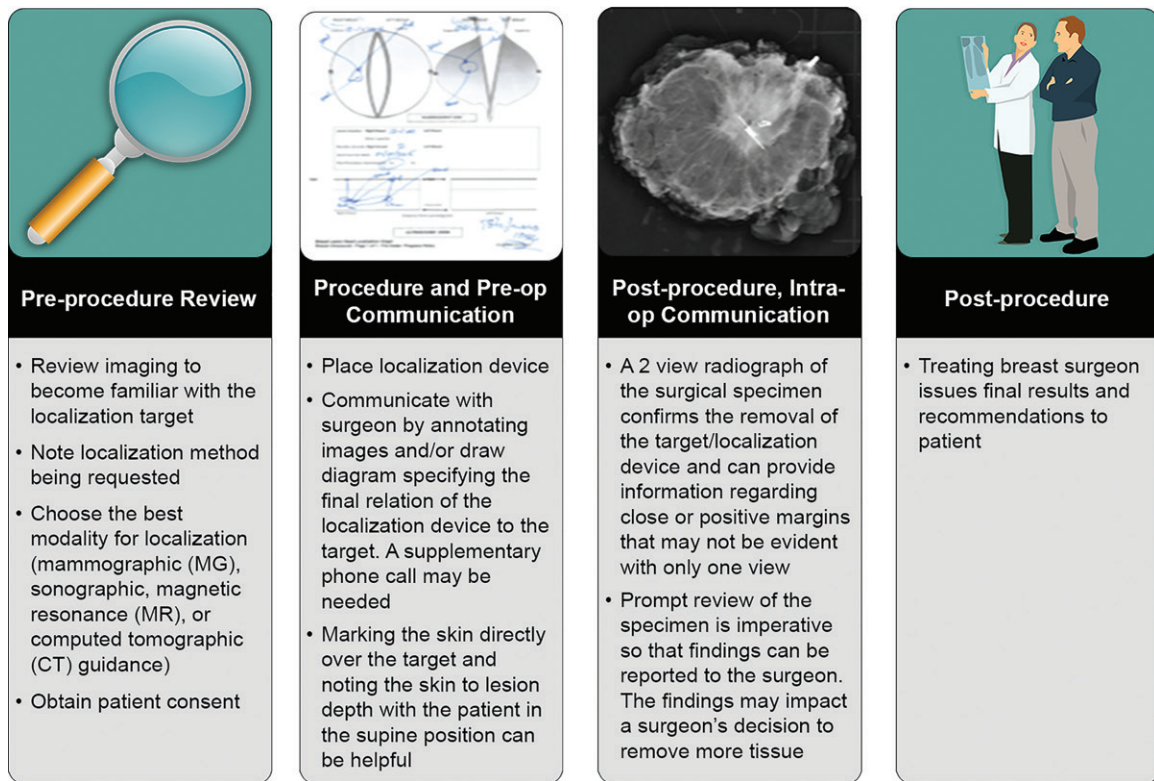


Figure 1. Overview of localization process.

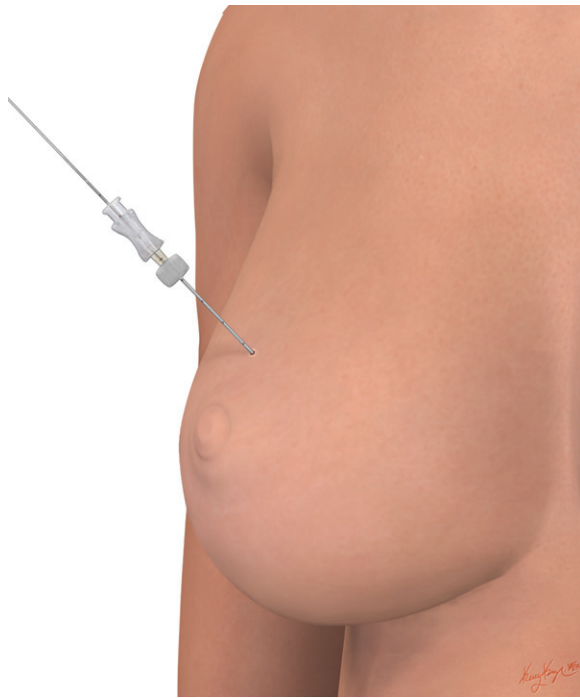target lesion(s) (4). On the basis of the requested localization technique, the radiologist will choose the best imaging modality for guiding the localization procedure. Typically, mammographic or sonographic guidance, rarely MRI or CT guidance, is used. Before the procedure, a discussion with the surgeon to review the tentative plan may be necessary in challenging cases, such as those involving the bracketing of an area of disease to ensure that the localization procedure will be the most helpful to the surgeon. Depending on the workflow at the radiologist's institution, informed patient consent to undergo the procedure is obtained by the surgeon as part of the preoperative consent protocol or by the radiologist on the day of the procedure.

During the procedure, the localization device is placed and a postprocedural mammogram typically is obtained to confirm the location of the device (6). The radiologist then summarizes the procedure for the surgeon by annotating images that depict the procedure in the picture archiving and communication System (PACS), drawing a diagram specifying the final relation of the localization device to the target, and/or annotating printed-out postprocedural film hard copies that will accompany the patient to the operating room (OR). The radiologist may consider calling the surgeon to discuss the procedure, particularly if the localization device is not in an

ideal position (3). Depending on the case, the surgeon may request that an additional device be placed. Marking the skin directly over the lesion and noting the skin-to-lesion depth and skin-to-localization device depth with the patient in the supine surgical position also can be helpful to the surgeon (3).

Intraoperatively, after the target tissue is excised, the specimen is labeled for orientation and radiographs are obtained to confirm the technically successful removal of both the target lesion and the localization device. These are usually either two 90° orthogonal radiographs of the en bloc specimen or an image of the en bloc specimen and an image of the sectioned specimen (7). These radiographs are helpful for assessing close or positive margins that may not be evident with only one view (8,9).

Intraoperative review of the specimen radiograph can yield important real-time feedback regarding the margins of the target lesion (6). By reviewing the specimen radiograph, the radiologist can aid the surgeon in determining whether additional tissue must be removed to ensure grossly negative margins. For example, if the targeted malignancy extends to a margin, this information can be communicated to the surgeon, who will then excise additional tissue to ensure that no residual disease remains in the breast. Prompt review of the specimen radiograph is



**Figure 2.** Drawing illustrates the appearance of the breast following the localization procedure, when it is requested that both the wire and the needle remain in place until the time of surgery.

imperative so that findings can be reported to the surgeon in a timely fashion. Postoperatively, the treating breast surgeon reviews the final histopathologic results and issues recommendations for the patient.

### Wire Localization

Wire localization has been the standard preoperative localization technique in the United States for decades. With this method, a wire is inserted percutaneously into the breast, with the distal wire segment positioned adjacent to the abnormality and the proximal wire segment remaining outside the breast. Wires can be placed by using mammographic, US, MRI, or CT guidance (10,11). The compatibility of the wire with MRI-guided deployment is an advantage of wire localization, as compared with other, nonwire localization devices. The imaging modality for guiding the procedure is chosen by considering how the target lesion is best seen and how to optimize patient comfort without compromising accuracy.

Wires are placed on the day of surgery. Multiple wires can be used either to bracket lesions larger than 2 cm, masses with satellite nodules, or accompanying microcalcifications extending from a mass or for segmental or linear distribution of microcalcifications alone (12). There is no restriction on the minimal distance between the wires when multiple wires are used to bracket an area of disease. Needle-wire systems with a variety of

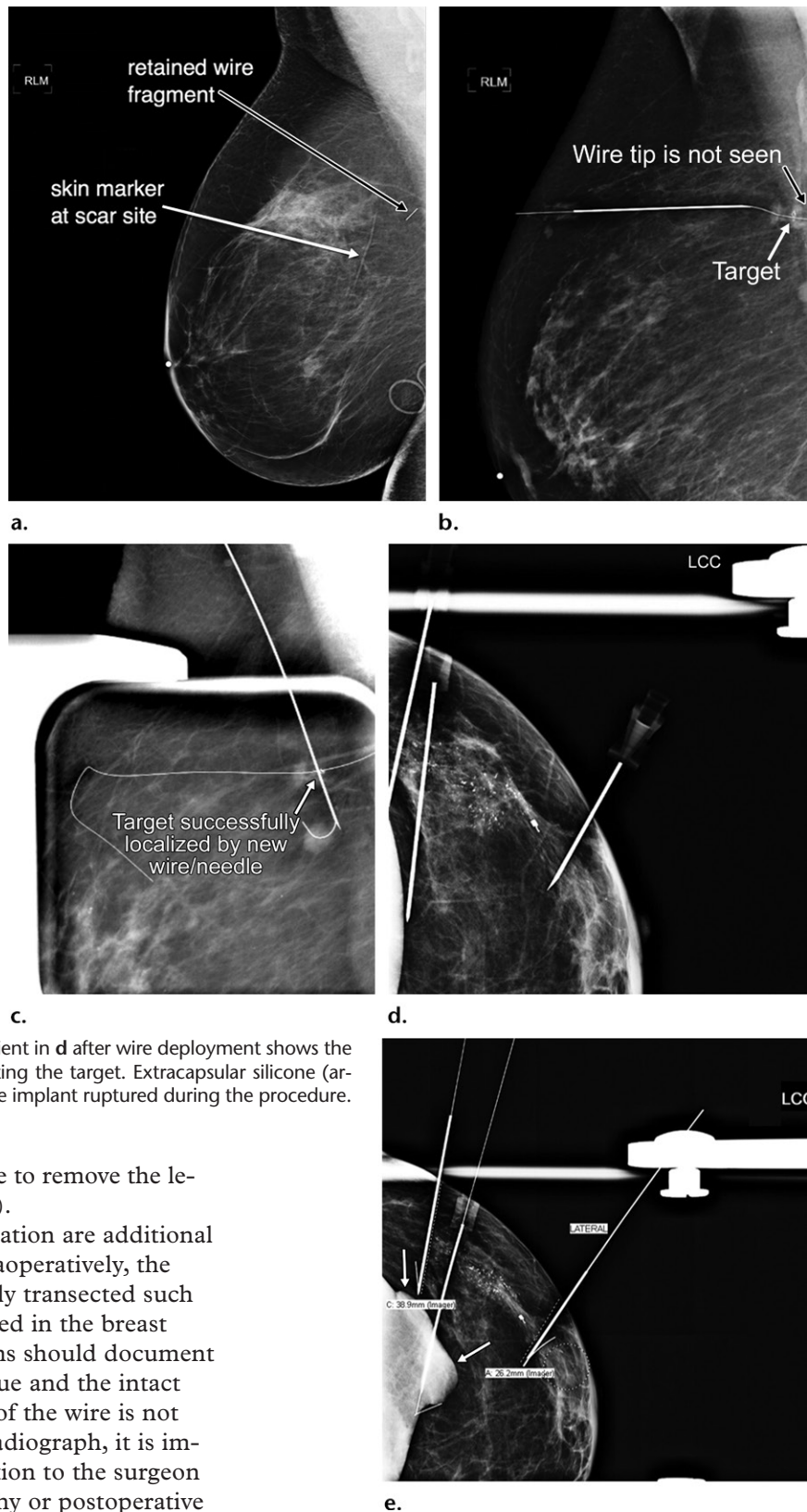
needle lengths (3–15 cm) and introducers (16–20 gauge) are available in single-use sterilized packages (3). The distal end of the wire can have different configurations, including hook, barb, or pigtail configurations, to anchor the wire near the target (3).

Generally, an introducer needle is inserted percutaneously into the breast under imaging guidance, with the needle tip positioned near the target. The introducer needle can be repositioned until the needle tip is at the targeted location. The needle hub is then held in place while the wire is introduced into the tissue through the needle, allowing the hook to deploy (13). Approximately 4–6 cm of the wire protrudes from the skin following the procedure (13). Depending on the surgeon's preference, the wire and introducer needle or the wire alone remains in the patient until the time of surgery (Fig 2). Given that the wire must remain in place from the time that it is deployed to the time of the surgical excision, this process requires significant patient compliance, because a portion of the needle and/or the wire will be outside the breast (3). In addition, although the wire and needle, or only the wire, will be secured to the breast with tape, the patient will be advised to try to minimize movement with the ipsilateral arm during transportation to the OR, as care must be taken to not disturb the wire position before surgery (14). Depending on the time of surgery, the needle(s) and/or wire(s) may be in the breast for several hours. Rates of clear surgical margins being obtained by using wire-localized excision range from 71% to 87% (15).

Although it is effective and relatively inexpensive, wire localization is associated with certain challenges and potential complications. From a scheduling and workflow perspective, wire localization procedures are challenging because they must be performed the morning of the surgery. This means that any number of factors may result in delayed surgery start times, including difficult or complicated localization procedures, unexpected delays in the radiology department, multiple patients with similar OR procedure times, and patient transport issues. Delayed OR procedure start times impair workflow efficiency, with potentially negative effects on revenue.

Other potential complications include but are not limited to pain at the wire site, hematoma development, vasovagal syncope, and nontarget tissue removal (3). Furthermore, the ideal wire entry site determined by the radiologist may not correspond with the ideal surgical incision site; thus, the wire location may affect the subsequent surgery (16). This decision is surgeon dependent, as some surgeons make their incisions separate from the wire entry point, while others make the

**Figure 3.** Wire localization complications in three patients. *LCC* = left craniocaudal, *RLM* = right lateromedial. (a) *RLM* mammogram after wire-localized excisional biopsy in a 61-year-old woman with a history of lobular carcinoma in situ shows a retained wire fragment adjacent to the excisional biopsy scar. This illustrates how the wire can be transected during surgery and result in a retained fragment. (b, c) *RLM* mammograms in a 76-year-old woman with invasive lobular carcinoma, obtained after she experienced vasovagal syncope following US-guided wire-needle localization of a clip in the right breast. (b) Postprocedural *RLM* mammogram shows the wire tip migrated beyond the posterior edge of the image. (c) A second wire-needle device inserted by using a craniocaudal approach with mammographic guidance enabled successful localization of the targeted biopsy clip. At surgery, the migrated wire tip was found in the pectoralis major muscle, and the migrated wire, second wire and needle, and known malignancy were excised. (d) *LCC* mammogram in a 55-year-old woman with invasive ductal carcinoma shows three needles placed from a lateral to medial approach to bracket calcifications and a clip in the side of the breast adjacent to a retropectoral silicone implant. The adjusted needle tips were positioned satisfactorily, so the wires were deployed. (e) *LCC* mammogram in patient in d after wire deployment shows the needles and associated wires bracketing the target. Extracapsular silicone (arrows) is observed, confirming that the implant ruptured during the procedure.



incisions directly over the wire to remove the lesion and the wire en bloc (10).

Wire transection and migration are additional potential complications. Intraoperatively, the thin wire may be inadvertently transected such that a wire fragment is retained in the breast (Fig 3). Specimen radiographs should document the retrieval of the target tissue and the intact wire (3). If the entire length of the wire is not visualized on the specimen radiograph, it is important to relay this information to the surgeon (3). Intraoperative radiography or postoperative imaging may be required to identify the retained wire fragment (3).

Migration of the wire within or beyond the breast after it is placed is another known complication (Fig 3) (3). Wire migration within the breast may compromise the removal of the target tissue. Wire migration beyond the breast may result in

injury to the affected tissues. For example, there are case reports that have described wire migration into the thoracic cavity causing pneumothorax and wire migration penetrating the pericardium resulting in delayed cardiac injury (4). For patients

with prepectoral implants, wire placement may be complicated by implant rupture (Fig 3).

### Nonwire Localization Techniques

Nonwire localization is a safe and effective alternative to wire localization that enables one to avoid some of the challenges associated with the wire procedure. Examples of nonwire localization devices are iodine 125 ( $^{125}\text{I}$ ) radioactive seeds (Advantage I-125; IsoAid, Port Richey, Fla), radar reflectors (Savi SCOUT; Cianna Medical, Aliso Viejo, Calif), magnetic seed markers (Magseed; Endomagnetics, Cambridge, England), and RFID tags (LOCALizer; Hologic, Marlborough, Mass) (Fig 4) (Table).

Nonwire localization systems have three components: a single-use 5–12-mm sterilized device preloaded into a 12–18-gauge needle introducer, a small reusable console, and a handheld intraoperative probe (Fig 4). Nonwire localization systems use send-receive technology at a specific wavelength in the electromagnetic spectrum (3). The probe is used in the OR to detect the localization device in the breast. The console emits real-time audio and visual feedback that aids the surgeon as he or she continues the dissection and advances closer to the target (3).

Nonwire devices may be deployed with mammographic, US, or CT guidance (3,10). Although nonwire devices cannot be deployed by using MRI guidance (10,17), patients may undergo MRI in appropriate conditions (18,19). The presence and size of device-related susceptibility artifacts vary according to device and sequence parameters, with the magnetic seed marker device having the largest signal void (3). Multiple nonwire devices can be used to bracket 2-cm or larger lesions, masses with satellite nodules, and/or accompanying microcalcifications extending from a mass, or for segmental or linear distribution of microcalcifications alone (12). During the placement of multiple devices, the devices should be approximately 2 cm apart to ensure that each one can be detected separately from the other (20,21). If the devices are too close, the surgeon may not be able to discern them as separate devices in the OR. Bracketing in the anteroposterior plane should be performed only after consultation with the breast surgeon, as the superimposed devices may appear intraoperatively as one source in the supine patient (6).

The most obvious advantage of using nonwire localization techniques is the absence of a wire. This can improve patients' experience because they do not have to sit with the needle-wire device partially outside the breast. Furthermore, the risk of wire migration and transection is eliminated.

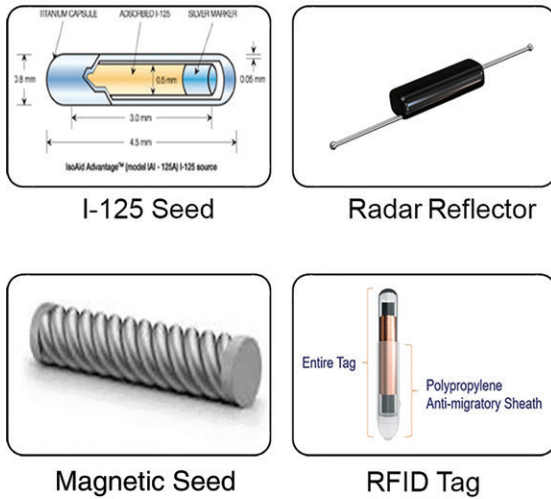
Another major advantage of using nonwire localization devices is that they can be placed in advance of the surgery date. Radioactive seeds can be placed up to 5 days before surgery, and because magnetic seeds, radar reflectors, and RFID tags have been approved for long-term (>30 days) placement, with the intent to remove them, there is no restriction on the length of time that they can remain in the breast. The advanced placement of these localization devices separates the imaging and surgery times. This allows more flexible scheduling of both procedures and prevents an imaging-related delay from affecting the surgery start time. Breast surgeries can be scheduled for any time of day, including as the first case of the day, since patients do not have to go to the radiology department the morning of their surgery. Thus, prolonged presurgical fasting can be minimized, and the associated increased risk of vasovagal syncope can be prevented (22).

An additional benefit of nonwire localization is continuous intraoperative reorientation to the target to keep it in the center of the specimen. This facilitates the potential removal of a smaller amount of nontargeted healthy tissue. With wire localization, the surgeon not only removes the target lesion but also retrieves the wire and the potentially healthy tissue along the course of the wire. Wire placement also affects the subsequent surgery because the wire must be retrieved. In contrast, with nonwire localization techniques, the surgical approach is not affected because there is no wire retrieval. The surgeon can use the probe to identify the localization device and thus choose the incision site closest to the lesion, minimizing nontarget tissue removal (16). The surgeon has more flexibility in choosing the incision location, and this may improve cosmesis (3). Similarly, from a radiologist perspective, because the entry site for placement of the localization device has no bearing on the incision, the radiologist can choose any skin entry site for accurate placement of the device (16).

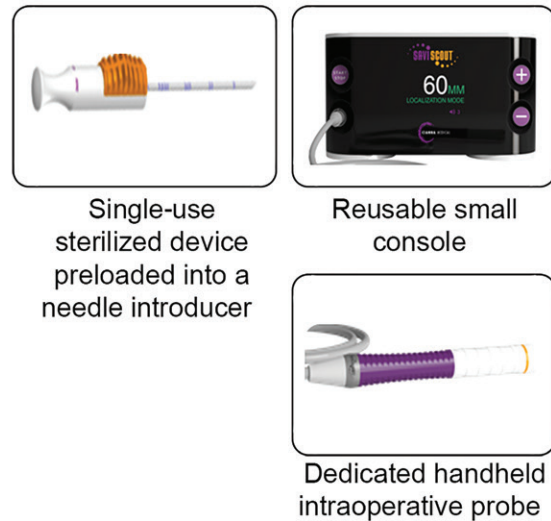
Nonwire localization techniques can also be used to guide lymph node removal in targeted axillary dissection procedures (23). This is more comfortable for the patient than the conventional wire localization method because there is no external device (23). To summarize, the advantages of nonwire localization techniques, as compared with wire localization, are improved scheduling flexibility, lack of a wire, potential to remove less nontarget tissue, potential for improved cosmesis, and improved access for targeted axillary node dissection.

Although nonwire localization techniques have certain advantages, each procedure is associated with a distinct set of challenges. Many of the

## Examples of NWL Systems



## NWL Systems Typically Have 3 Components



**Figure 4.** Diagrams and photographs of nonwire localization (NWL) devices (left) and the three main components of a nonwire localization system (right). (Images were reprinted, with permission, from Isoaid [<sup>125</sup>I seed], Endomagetics [magnetic seed], Hologic [RFID tag], and Cianna Medical [radar reflector, single-use sterilized device, reusable console, handheld intraoperative probe].)

disadvantages of using nonwire localization are related to the devices themselves. These devices cannot be repositioned, and they cannot yet be placed with MRI guidance. If a nonwire localization device is incorrectly positioned, placement of a second device may be required and thus result in the removal of nontargeted tissue (24). The spacing of the devices is a necessary consideration when lesion bracketing is required.

The detectability of nonradioactive devices in the OR may be limited by the depth of the device from the skin. The reported ranges of device detection depth are related to supine positioning for surgery. These values will potentially differ from the observed skin-to-device depth if they are measured at mammography, so radiologists should be aware that an imaging-based measurement greater than the device recommendations may not mean that the device will not be detected.

Any change in practice with regard to the localization technique requires multidisciplinary collaboration and communication among the radiology, surgery, and pathology teams. From a surgery perspective, implementing a new localization system requires an initial capital investment in the reusable console and probe, which are the most expensive components. The involved personnel, including but not limited to radiologists and surgeons, will require training to successfully use the chosen nonwire localization system. Cost considerations include initial and ongoing purchases of the single-use localization devices, which are more expensive than wires. Despite the equipment and device costs,

nonwire localization systems may not necessarily be unfavorable from a cost-benefit perspective. The elimination of OR delays associated with wire localization may translate to cost savings. Using a Monte Carlo simulation, Loving et al (25) found that using radioactive seed localization (RSL), as compared with wire localization, resulted in a lower total health care cost in a bundled payment system.

### Radioactive Seed Localization

RSL was first described as an alternative to wire localization in 2001 (16). A radioactive seed is a 5-mm <sup>125</sup>I-labeled, titanium-encased implant (16) (Fig 5). At the time of surgery, a handheld gamma probe set to detect a 27-keV <sup>125</sup>I source identifies the seed location (16). Loose radioactive seeds can be loaded into a needle occluded with bone wax at the tip or purchased preloaded in needles (23). The seeds can be placed up to 5 days before the planned surgery (26). Rates of clear surgical margins obtained by using RSL-guided excision range from 74% to 97% (27–29).

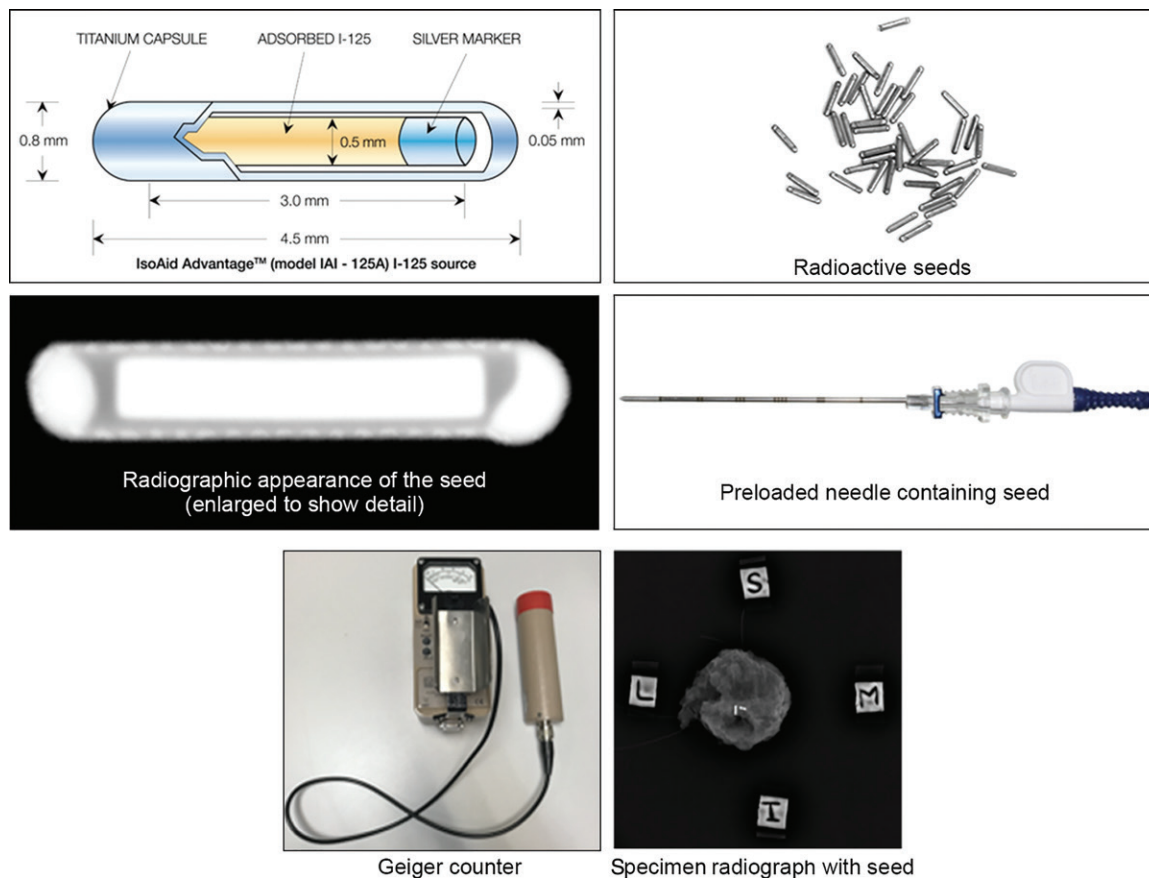
RSL has many benefits and advantages. In terms of surgical outcomes, some researchers (16,27,29) have found that patients who undergo RSL have lower positive margin rates and thus need substantially fewer repeat excisions than do patients who undergo wire localization. This finding is attributed to the surgeon's ability to constantly reorient the surgical dissection toward the seed's position by using the gamma probe intraoperatively (16). Other researchers have demonstrated no difference in positive margin

Features of Wire and Nonwire Localization Techniques

Feature	Localization Device				
	Wire	<sup>125</sup> I Radioactive Seed	Radar Reflector	Magnetic Seed	RFID Tag
Needle gauge	20–21	18	16	18	12
Needle length (cm)	3–15	5, 7, 12	5, 7.5, 10	7, 12	5, 7, 10
Device length (mm)	...	5	12	5	9
Device cost (\$)	20–25	5–100	400–500	400	274
Additional equipment requirements	None	OR gamma probe and console Geiger counter	OR detector probe and console Radiology suite probe and console	OR detector probe and console Nonferromagnetic surgical instruments	OR console and single-use surgical probe
Depth limit for detectability (cm)	None	None	6	4	3–6
Maximal duration of implantation (d)	0	5	>30	>30	>30
MRI safety	MRI-compatible wires are available from multiple vendors	MRI conditional	MRI conditional	MRI conditional	MRI conditional
Strengths	Least expensive device No depth limitation No minimal spacing for lesion bracketing Is the only device that can be placed with MRI guidance	Console and probe for RSL are already present in most ORs and can be used for concurrent sentinel lymph node biopsy Breast and axillary node localization No depth limitation Small size Outcomes similar or better than those with wire localization	Long-term implantation Breast and axillary node localization Minimal susceptibility artifact at MRI Outcomes were similar to those with wire localization in one study*	Long-term implantation Breast and axillary node localization Deployment similar to biopsy clip Small size Same console and probe can be used for sentinel lymph node biopsy	Long-term implantation Each tag has a unique identification number that is visible on the console Pencil-sized surgical probe
Weaknesses	Presurgical patient will be in fasting state, vasovagal reactions Multiple known complications Potential patient discomfort while waiting for surgery Scheduling inflexibility	Radiation exposure to patient and personnel Lengthy process to begin program Regulatory requirements, licensing, need for radiation safety officer supervision	Multiple factors may limit signal detection in OR Potential for allergic reaction for patients with known nitinol allergy	Susceptibility artifact at MRI Contraindicated in patients with implanted cardiac devices Nonmagnetic surgical tools are needed because ferromagnetic instruments interfere with signal	Axillary node localization considered off label Single-use surgical probe

\*Source.—Reference 13.





**Figure 5.** Components used in RSL. Top: Drawing of a labeled radioactive seed (left) and image of loose radioactive seeds (right). Middle: Radiographic appearance of the seed (left) and image of a preloaded needle containing the seed (right). Bottom: Photograph of a Geiger counter used to detect radioactivity (left) and specimen radiograph depicting the radioactive seed and localization target (right). I = inferior, L = lateral, M = medial, S = superior. (Drawing of the labeled seed and images of the loose radioactive seeds and preloaded needle were reprinted, with permission, from Isoaid.)

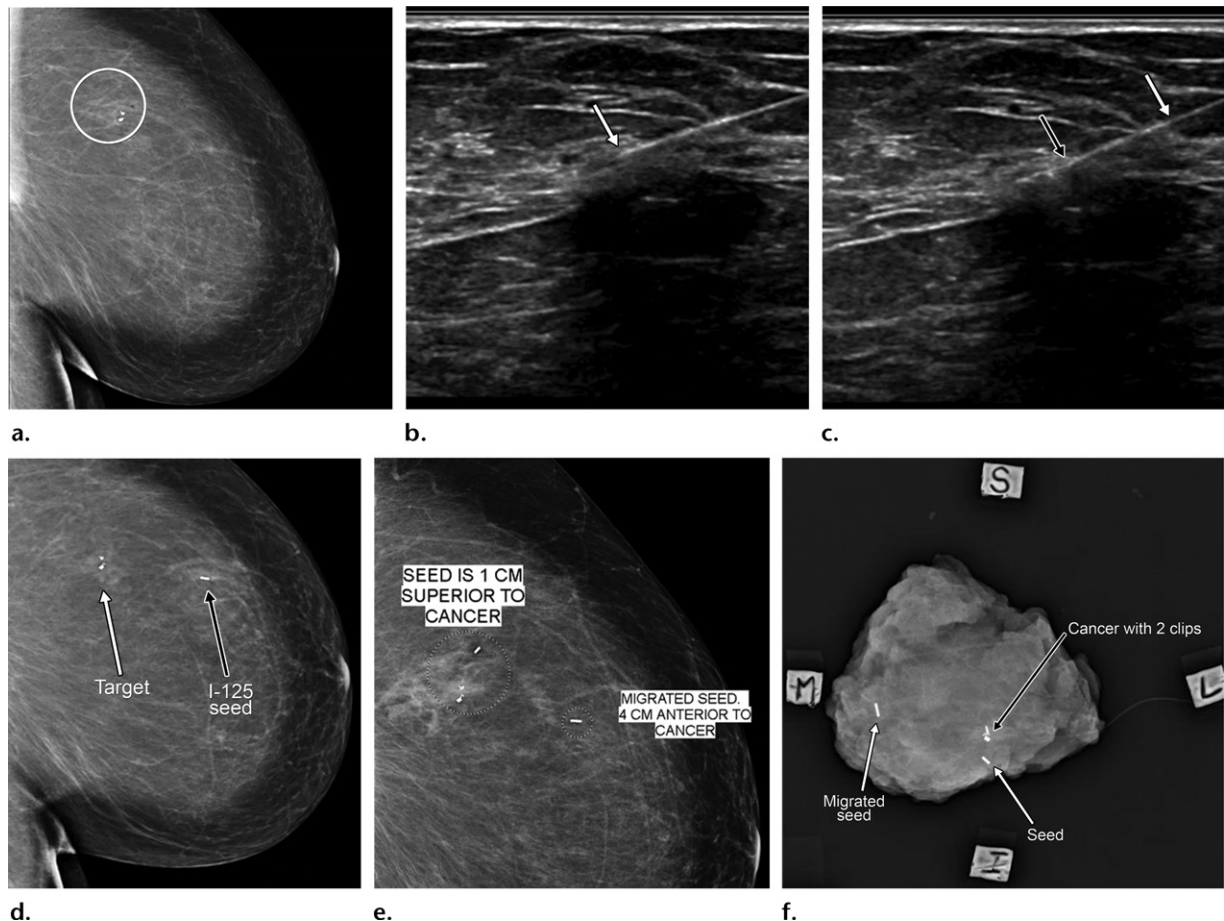
rates between patients who undergo RSL and those who undergo wire localization (30).

From a patient perspective, the convenience of having a radioactive seed placed before surgery was reflected in the results of a patient satisfaction survey (28). Patients who undergo RSL have fewer vasovagal reactions than do those who undergo wire localization, probably because they are not in a fasting state (31). From a technical perspective, a benefit of RSL is the ability to perform sentinel lymph node biopsy concurrently (27). The technetium 99m isotope commonly injected for localization of sentinel lymph nodes for sentinel node excision emits 140 keV of gamma energy, whereas the  $^{125}\text{I}$  in a radioactive seed emits 27 keV of gamma energy (27). This peak separation allows separate identification of the two radiation sources when they are used simultaneously by adjusting the activity detection setting on the probe (10,27). In addition, unlike with other nonwire localization techniques, with RSL there is no reported depth limitation for detectability. With regard to workflow, researchers have found the use of RSL, as compared with

wire localization, to be associated with better workflow (31,32). From a financial perspective, research results (31) have shown that the costs associated with RSL are lower than those associated with wire localization.

The caveats of using RSL are related to the radioactivity involved. An RSL program must follow strict regulations for use of nuclear materials issued by the Nuclear Regulatory Commission. Owing to the regulatory requirements, it can take years to establish a radioactive seed program. This is in contrast to the time required to establish other nonwire localization programs, which can be set up relatively quickly because there are no regulatory requirements. In an RSL program, all involved practitioners must undergo annual radiation safety training and a radiation safety officer must oversee the program.

There are additional procedural steps related to the radioactivity involved that are specific for RSL. For example, before seed insertion, an initial radiation survey is performed by using a Geiger counter to confirm the seed radioactivity in the needle and lack of radioactivity in the pa-



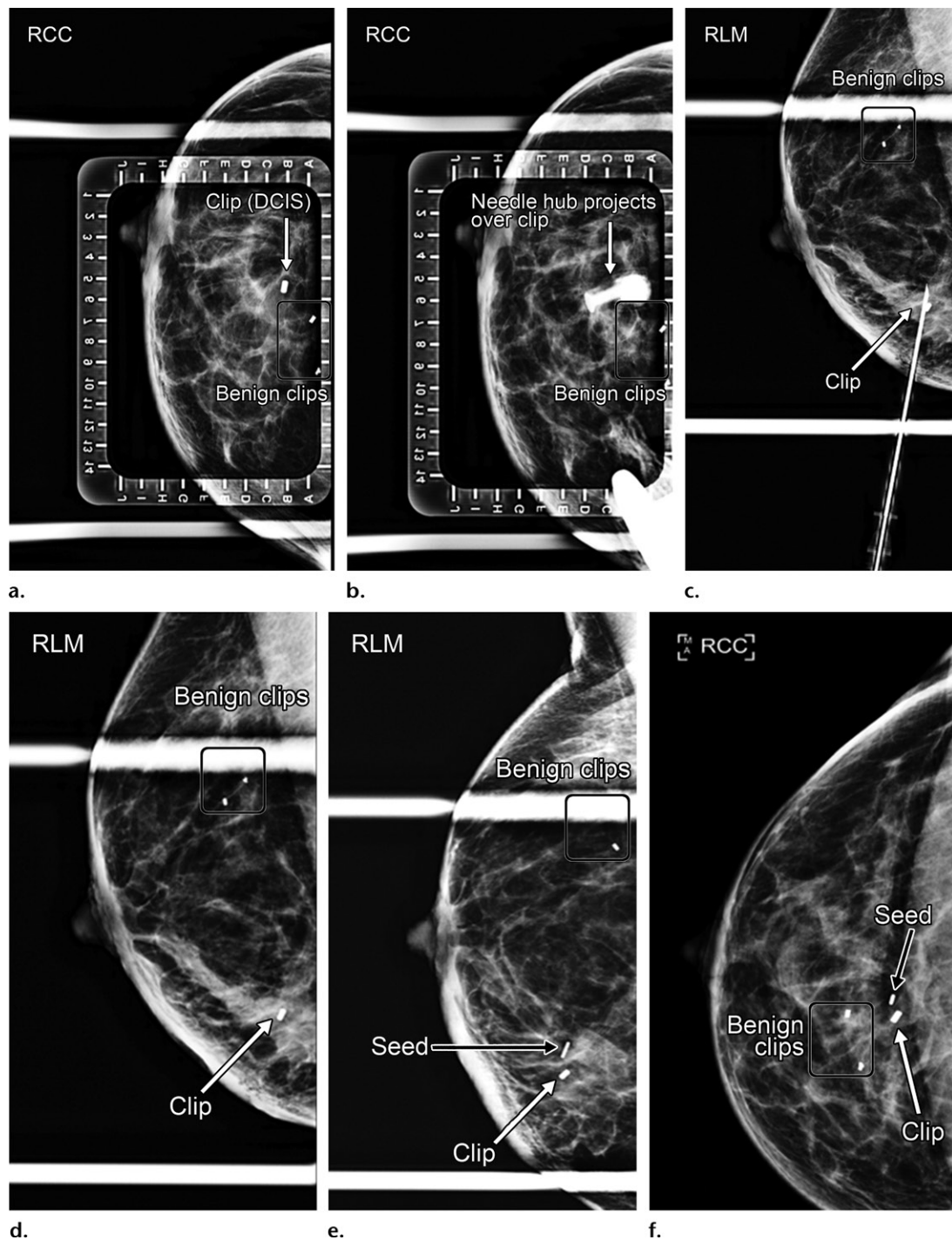
**Figure 6.** Radioactive seed migration in a 45-year-old woman with invasive ductal carcinoma who underwent RSL. (a) Left latero-medial (LLM) mammogram shows two clips in proximity to the known malignancy (circle) at 10-o'clock posterior depth in the left breast. (b) A residual mass was noted at US, and RSL was performed with US guidance. Static US image shows the tip of the needle introducer (arrow), which contains the seed, in the mass. (c) Static US image shows the radioactive seed (black arrow) deployed in the mass after being pushed out of the needle introducer (white arrow). (d) Postprocedural LLM mammogram shows the  $^{125}\text{I}$  seed 4 cm anterior to the target. When the introducer needle was removed from the breast, the seed was pulled back along the path of the needle. Once deployed, the seed cannot be repositioned. The surgeon was notified by phone of the need to retrieve the initially inserted seed, which had migrated, and place an additional seed. (e) LLM mammogram shows a second radioactive seed placed with mammographic guidance by using a craniocaudal approach. The second seed is 1 cm superior to the cancer. The ideal seed position is within 5 mm of the target, while 5–10 mm from the target is acceptable and more than 10 mm from the target warrants surgeon notification to decide whether another seed should be placed. In this case, the surgeon was comfortable with the seed position. (f) Specimen radiograph findings confirmed successful removal of both radioactive seeds and the malignancy with associated biopsy clips. This case illustrates seed migration immediately after deployment, the essential role of mammography after seed placement, and the importance of communicating with the surgeon if there is any issue regarding the seed position. The total number of seeds placed should always be specified so that the appropriate number of seeds can be confirmed as successfully removed when the specimen radiograph is reviewed. *I* = inferior, *L* = lateral, *M* = medial, *S* = superior.

tient. Once the seed is deployed, a Geiger counter is used to examine the patient to confirm the presence of radioactivity, and to examine the needle to confirm the absence of radioactivity (22).

Unlike a migrated biopsy clip, a migrated radioactive seed must be recovered (Fig 6). After the seed is retrieved from the excised specimen, it must be placed in a lead container and sent back to the nuclear medicine service for safe disposal. Seeds can be transected during specimen slicing for histopathologic analysis (33). Unlike other nonwire localization devices, a radioactive seed requires careful scrutiny for management of contaminated areas if it is transected. If an inserted

seed is not removed within 5 days after it is placed, the radiation safety officer must be notified and the patient must be monitored until it is removed.

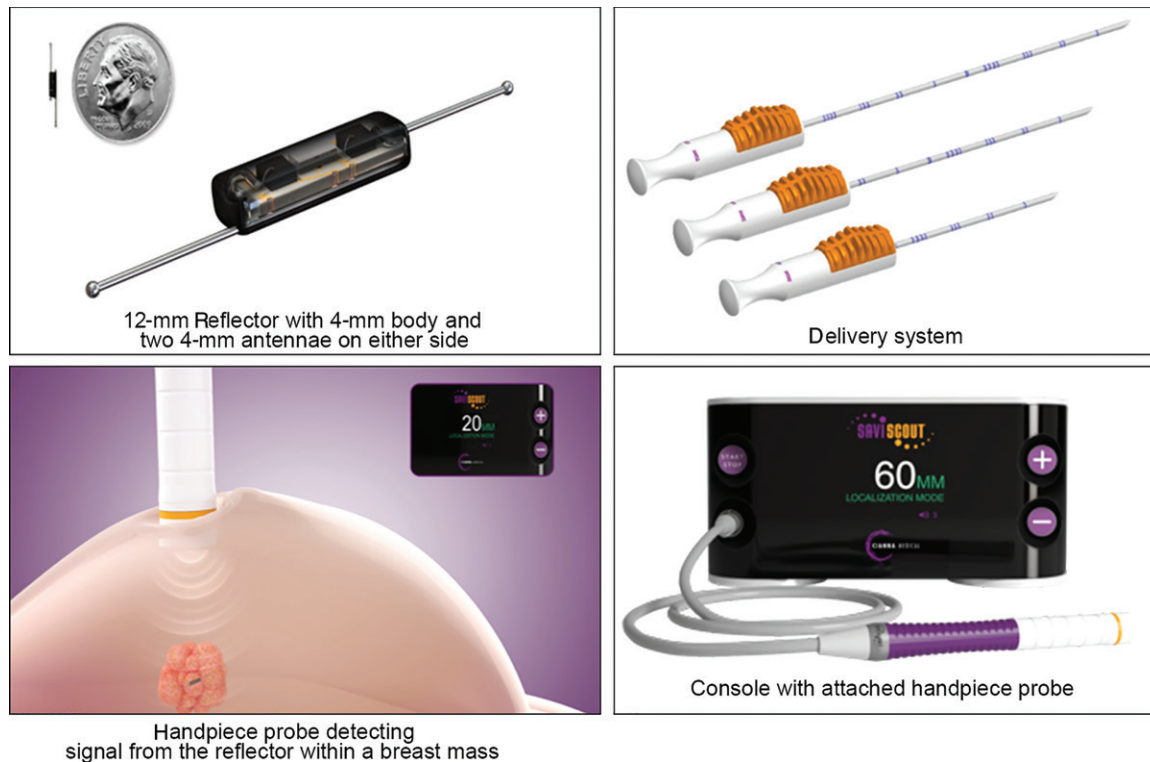
Another issue to consider is the loss of a radioactive seed, which unlike the loss of other localization devices, is a reportable medical event (Fig 7). Thus, an established protocol is needed to manage this situation. In the event that a radioactive seed is lost, a written protocol should be available to guide personnel on what to do next. The imaging suite, OR, and pathology laboratory should each have protocols to follow if a seed is lost. The following is an example imaging suite protocol for a lost radioactive seed:



**Figure 7.** Lost radioactive seed in a 52-year-old woman with right breast ductal carcinoma in situ, diagnosed by using MRI-guided biopsy, who underwent RSL. (a) RCC mammogram with alphanumeric grid shows a target clip marking the site of biopsy-proven ductal carcinoma in situ (DCIS) at the B5 location. Clips marking the sites of remote benign-result biopsies (rectangular outline) also are present. (b) RCC mammogram with alphanumeric grid shows placement of the needle with a caudocranial approach. The needle hub projects over the target clip. (c) After initial insertion of the needle from below, the breast was compressed in the orthogonal lateromedial position, and an RLM mammogram was obtained. The needle tip was adjusted to an ideal position adjacent to the target clip, the seed was deployed, and the needle was removed. (d) RLM mammogram after seed deployment shows the clip, but the seed is not visualized. When the introducer needle was pulled out, the seed was pulled back and fell out when the needle was removed from the breast. The imaging suite's lost seed protocol was followed, with the seed ultimately found on the floor. (e, f) RLM and RCC mammograms show technically successful second-attempt seed placement adjacent to the clip.

(a) All personnel must stay inside the imaging suite until the seed is recovered. (b) The radiation safety officer is alerted. (c) The appropriate

radiation survey device is used to locate the seed. (d) The needle assembly, patient, drapes, patient bed, and floor are checked for the missing seed



**Figure 8.** Components of a radar reflector localization system. (Images reprinted, with permission, from Cianna Medical.)

by using the survey device. (*e*) When the seed is found, flat-end tweezers are used to retrieve and handle it. (*f*) The seed is placed inside a properly shielded container and returned to the nuclear medicine service. If a seed is determined to have been lost after following this protocol, the radiation safety office must submit a report to the appropriate agency within 30 days. This event could jeopardize the future status of the RSL program.

The following are practical tips for performing RSL: Keep the safety component of the radioactive seed introducer needle in place as long as possible to limit accidental seed deployment. To optimize accurate placement of the seed, position the distal needle tip just proximal to the target, with the bevel pointed toward the target before the seed is deployed. When performing RSL, do not discard any material used in the seed placement procedure until mammogram findings confirm the placement. If a seed is placed with US guidance, do not use the US room until the seed placement in the breast is confirmed on the postprocedure mammogram. This will aid in the recovery if a seed is lost.

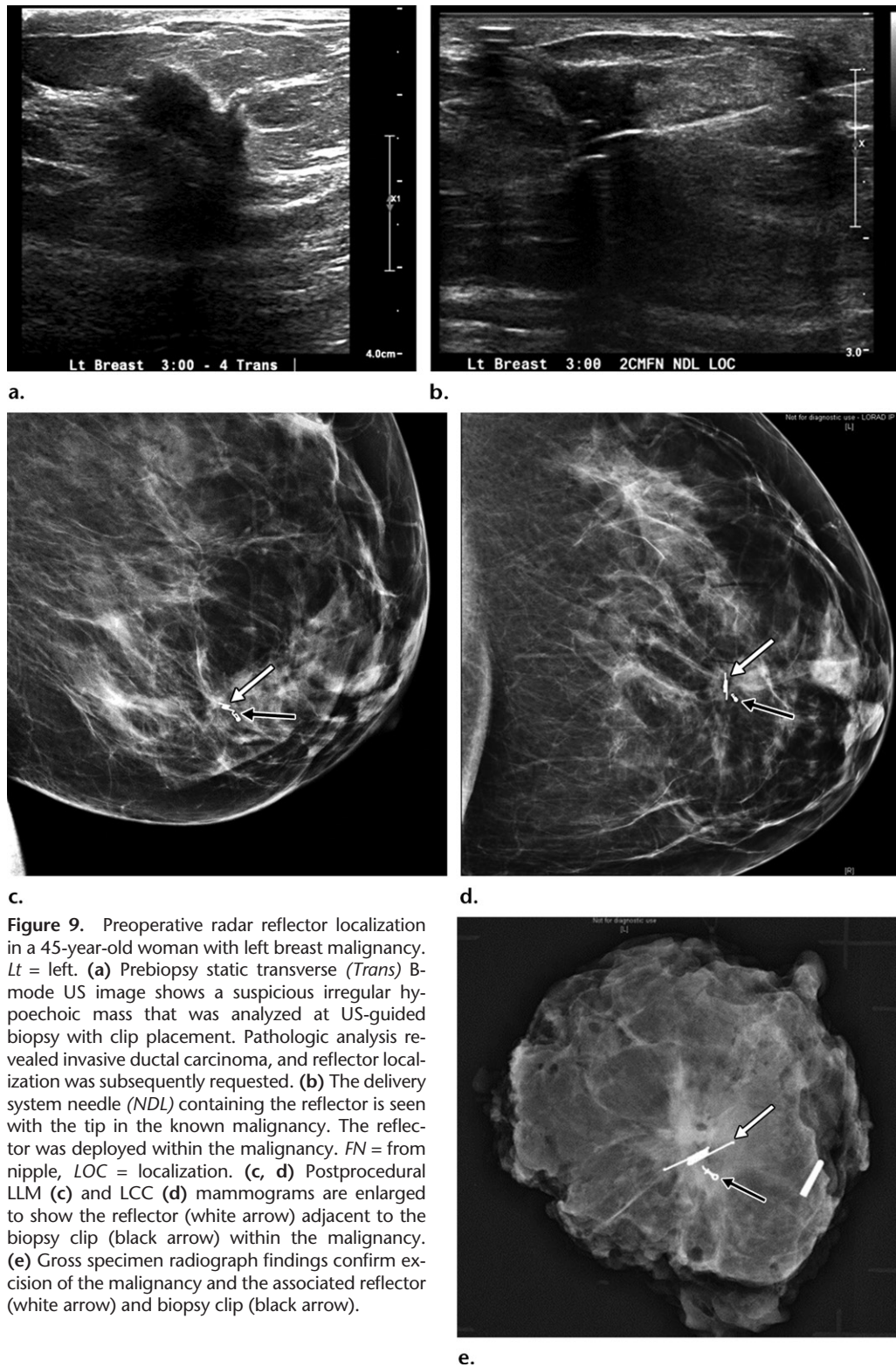
RSL offers all of the major advantages of nonwire localization techniques, without detection being limited by the seed's depth from skin. However, the substantial number of regulations for using nuclear materials limits the widespread adoption of this localization technique and is associated with specific challenges. Some of the

limitations of RSL are addressed by using nonradioactive nonwire localization devices, including radar reflectors, magnetic seeds, and RFID tags.

### Radar Reflector Localization

Radar localization technology was introduced in 2014 (Fig 8). The Savi SCOUT radar reflector is 12 mm in length and includes two antennae, an infrared light receptor, and a transistor switch (Fig 8) (34). The reflector antennae are constructed of nitinol, a robust shape-memory material (35). The reflector is preloaded into a 16-gauge introducer needle (13). To prevent antennae bending, the reflector is deployed by withdrawing a release button rather than pushing the reflector forward (Fig 9) (34). The radiologist uses a console to ensure that an audible signal can be obtained from the device (36). While use of the RFID tag and magnetic seed devices can cause MRI susceptibility signal void artifact, the radar reflector device causes minimal signal void artifact (3).

In the OR, the detector console sends the microimpulse radar signal to the handpiece and emits power for the infrared light sources (18). The handpiece delivers the microimpulse radar signal and infrared light to the breast tissue (18). This signal is received by the infrared light receptor within the reflector (34). The reflector is passive until it is activated with infrared light from a dedicated probe. Next, a transistor



**Figure 9.** Preoperative radar reflector localization in a 45-year-old woman with left breast malignancy. *Lt* = left. **(a)** Prebiopsy static transverse (*Trans*) B-mode US image shows a suspicious irregular hypoechoic mass that was analyzed at US-guided biopsy with clip placement. Pathologic analysis revealed invasive ductal carcinoma, and reflector localization was subsequently requested. **(b)** The delivery system needle (*NDL*) containing the reflector is seen with the tip in the known malignancy. The reflector was deployed within the malignancy. *FN* = from nipple, *LOC* = localization. **(c, d)** Postprocedural LLM **(c)** and LCC **(d)** mammograms are enlarged to show the reflector (white arrow) adjacent to the biopsy clip (black arrow) within the malignancy. **(e)** Gross specimen radiograph findings confirm excision of the malignancy and the associated reflector (white arrow) and biopsy clip (black arrow).

switch connected to the antennae closes, and this results in the reflection of an electromagnetic wave signal back to the handpiece (34). The console then processes the reflected radar signals to provide the surgeon with reflector proximity information in the form of audible and visual feedback (24).

The radar reflector has a depth detection range of at least 6 cm and enables real-time distance measurement at an accuracy of plus or minus 1 mm (18). Most breast lesions are within the targeted depth when the patient is in the supine surgical position (34). Researchers have successfully detected reflectors at a depth of up to 8 cm (37). A deeper

reflector can be detected by applying additional compression to tissue with use of the handpiece.

Falcon et al (36) had a 97% success rate with 148 reflectors in 125 women, with *success* defined as accurate device placement in relation to the target, a detectable signal in the imaging suite, a detectable signal in the OR, and confirmed removal of the localization target and reflector at specimen radiography. Clear surgical margin rates achieved by using radar reflector–guided excision have ranged from 85% to 93% (13,35,37). Researchers in a recent study (13) in which the surgical outcomes of radar reflector localization were directly compared with those of wire localization found no substantial differences in outcome measures, including margin positivity, close margin, and re-excision rates. Cox et al (37) found that of patients who completed a postprocedural survey, 71% were very satisfied with the radar reflector localization procedure and 97% would recommend it to other patients.

There are some caveats regarding the use of radar reflector localization. Failures related to this localization technique typically are due to a lack of signal from the device (36). Dense objects between the reflector and handpiece, such as calcified masses, hematomas, or localization wires, can weaken or interfere with signal detection (35,36). In one feasibility study (34), a significant reflector migration was demonstrated in a patient with a postbiopsy hematoma. In such scenarios, it may be necessary to place the reflector adjacent to the hematoma to ensure that it can be successfully retrieved (35). Certain plastics also may interfere with the signal (36).

In one study (37), halogen and some older-model OR lights were shown to affect detection of the reflector. However, simply shielding the breast from the lights or redirecting the lights away from the breast while using the handpiece allowed full detection of the reflector, so this was not considered a contraindication. LED lights are more prevalent than halogen lights in ORs, and they did not interfere with localization of the reflector in the aforementioned study (37). In addition, radar reflector antennae are made of nitinol, an alloy of nickel and titanium. Thus, with all devices containing nitinol, the manufacturer includes the U.S. Food and Drug Administration precautionary statement warning that there is potential for an allergic reaction for patients with known allergies to nitinol.

If the radiologist cannot detect a signal after the reflector is placed, certain steps may be helpful. These steps include repositioning the patient, slowly moving the handpiece, and ensuring that the handpiece is not covered in sterile plastic (36). In addition, the needle assembly can be

checked to assess for proper device deployment. If the localization was performed with US guidance, postprocedural mammography should be performed. Finally, the OR console can be used to assess for a signal, as it may differ technically from the console in the imaging suite (36).


The following are practical tips for using the radar reflector localization procedure: To ensure that the center of the reflector is at the desired location within the target, position the delivery needle 6 mm distal to the geometric center of the target; then pull the release button to leave the reflector in the expected location. The radiologist should use the console to check for a signal after the procedure and know what to do when one is not detected. When a hematoma is present at the time of localization, the position of the device in relation to the hematoma must be considered.

Radar reflector localization is advantageous, as compared with RSL, because of the lack of radioactivity, lack of regulatory issues, and potential for long-term implantation of the reflector. This device is also advantageous because there are minimal artifacts at MRI. However, the reflector device should not be placed within or deep to a hematoma. In addition, because the reflector antennae contain nitinol, there is potential for an allergic reaction in patients known to be allergic to nitinol.

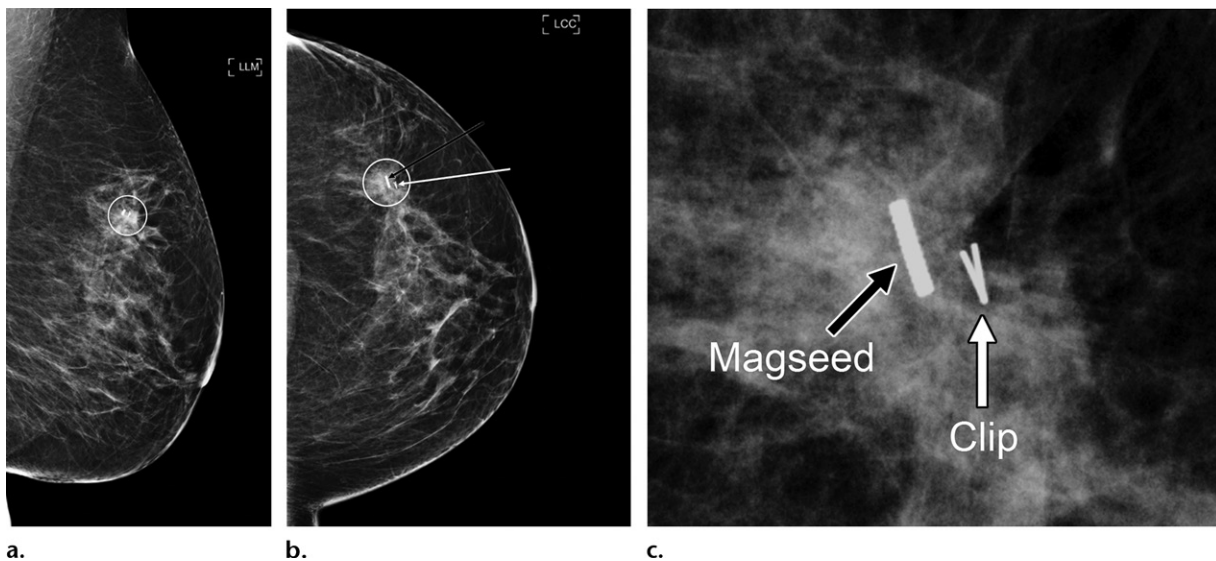
### Magnetic Seed Localization

A commonly used magnetic seed (Magseed) is a  $5.0 \times 0.9$ -mm localization device made of stainless steel that was introduced in 2016 (Fig 10). The seed is retained in the delivery needle with a wax plug (38). Similar to a radioactive seed or clip marker, the magnetic seed is deployed from the end of the needle (Fig 11). The seed itself is not magnetic, but it can be induced to become a magnet under the influence of a probe (Sentimag; Endomagnetics) (38). The probe produces an alternating magnetic field that transiently magnetizes the iron within the magnetic seed (38). The probe unit provides audible feedback and a numeric value for the strength of the magnetic field and thus estimates the distance of the seed from the probe (21,38). The magnetic seed can be detected at a distance of up to 3–4 cm from the probe (21). The clear surgical margin rate achieved by using magnetic seed–guided excision is reported to be approximately 83% (21). In a study involving 137 malignancies (39), 30 (21.9%) of these tumors had positive or close surgical margins.

Similar to the radioactive seed and radar reflector techniques, magnetic seed localization can be used for both breast and axillary node localizations (Fig 12). With magnetic seed localization, as with radar reflector localization, the limitations of RSL



**Figure 10.** Components of a magnetic seed localization system. (Images adapted and reprinted, with permission, from Endomagnetics.)



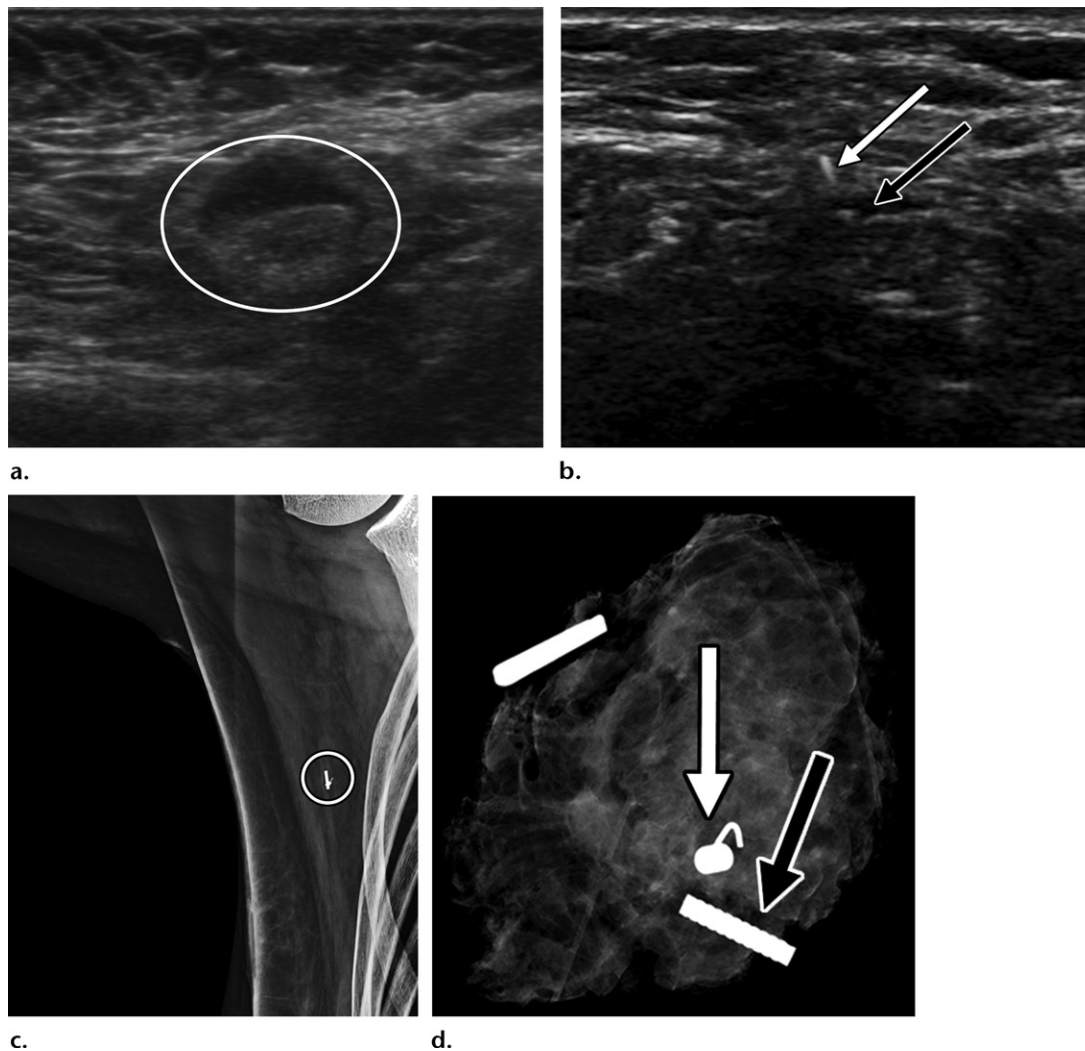
**Figure 11.** Magnetic seed localization in a 50-year-old woman with invasive mammary carcinoma. (a, b) Postprocedural LLM (a) and LCC (b) mammograms show the magnetic seed (black arrow in b) adjacent to the biopsy clip (white arrow in b) within the target lesion (circle). (c) LCC mammogram in b is enlarged to show the magnetic seed, which has serrated edges, adjacent to the biopsy clip.

that are related to radioactivity and regulatory burden can be avoided, allowing ease of program start-up. Therefore, this procedure, as compared with RSL, potentially could be used in a larger number of clinical settings (10).

The probe can also be used to perform lymphatic mapping and sentinel node biopsy with use of superparamagnetic iron oxide nanoparticles (40,41). Using magnetic seed localization and superparamagnetic iron oxide nanoparticles results

in a totally magnetic technique, as opposed to magnetic seed breast localization combined with radioisotope lymphatic mapping, which requires the use of two separate probes and nuclear medicine resources (41).

In a study involving 188 women, 206 (96.7%) of 213 magnetic seed markers were successfully placed within 1 cm of the target lesion (39). This included 24 cases involving the placement of multiple seed markers located an average of



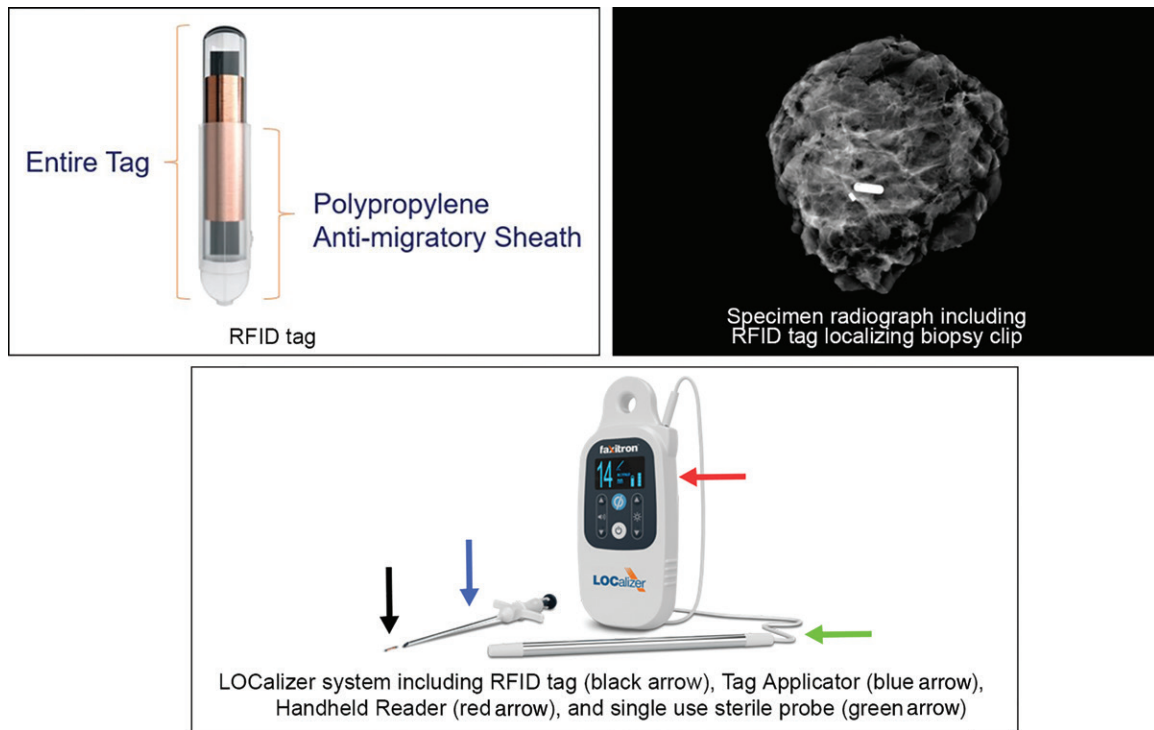
**Figure 12.** Magnetic seed localization of a clipped biopsy-proven metastatic axillary lymph node in a 49-year-old woman with T3N1M0 invasive ductal carcinoma after she completed neoadjuvant chemotherapy. **(a)** Static B-mode US image obtained before biopsy and neoadjuvant chemotherapy shows the metastatic axillary lymph node (oval) with a thickened cortex. **(b)** Static B-mode US image obtained after neoadjuvant chemotherapy and before magnetic seed placement shows the echogenic marker clip (white arrow) adjacent to the metastatic axillary lymph node, which has a benign appearance and a thin cortex (black arrow) after treatment. **(c)** Right mediolateral oblique mammogram shows the magnetic seed adjacent to the clip marker in the axilla (circle). **(d)** Specimen radiograph of the surgical axillary specimen shows the magnetic seed (black arrow) and the marker clip (white arrow).

29 mm apart, with some seeds as close as 3 mm apart, and all seeds were successfully retrieved (39). The magnetic seeds that were more than 1 cm from the target lesion were placed by using mammographic (specifically tomosynthesis) guidance, and they probably migrated owing to accordion effect (39). Suggested techniques to avoid this migration include using the smallest possible amount of compression during the procedure and slowly releasing the compression after magnetic seed deployment (39).

Use of magnetic seed localization is associated with some caveats. For example, it cannot be used in patients who have a pacemaker or implanted chest wall device. With regard to depth

detection, the reported limit is 4 cm, which is lower than the depth detection limits with RSL and radar reflector localization. However, seeds have been detected in locations deeper than this reported limit (21). There are also intraoperative considerations. Nonferromagnetic surgical tools must be used while the probe is in use, because ferromagnetic instruments will interfere with the signal (42). Some reaction to bone wax, which is made of beeswax, may occur. This reaction, which can be an allergic or foreign body response, occurs because bone wax is a minimally resorbable implantable substance (43). The substantial susceptibility artifact associated with magnetic seeds is a consideration in the preoperative setting





**Figure 13.** Components of RFID tag localization system. (Images adapted and reprinted, with permission, from Hologic.)

for patients who require breast MRI (3,38). In the feasibility study by Harvey et al (38), patients were not offered magnetic seed placement until after the necessary MR images were obtained.

The following are practical tips for magnetic seed localization: To ensure that the seed is at the desired location in relation to the target, position the needle tip just proximal to the geometric center of the target and then deploy the seed. To limit accidental seed deployment, keep the safety component of the introducer needle in place until the needle tip is at the desired location.

A magnetic seed is the smallest nonradioactive localization device and offers advantages that are similar to those offered by other nonradioactive nonwire localization techniques. Because ferromagnetic instruments will interfere with the signal when the probe is in use, nonferromagnetic surgical instruments are necessary. However, the use of these tools may result in additional start-up costs (42). Use of a magnetic seed and superparamagnetic iron oxide with the probe results in a completely magnetic nonradioactive technique for breast and sentinel lymph node surgery.

### RFID Tag Localization

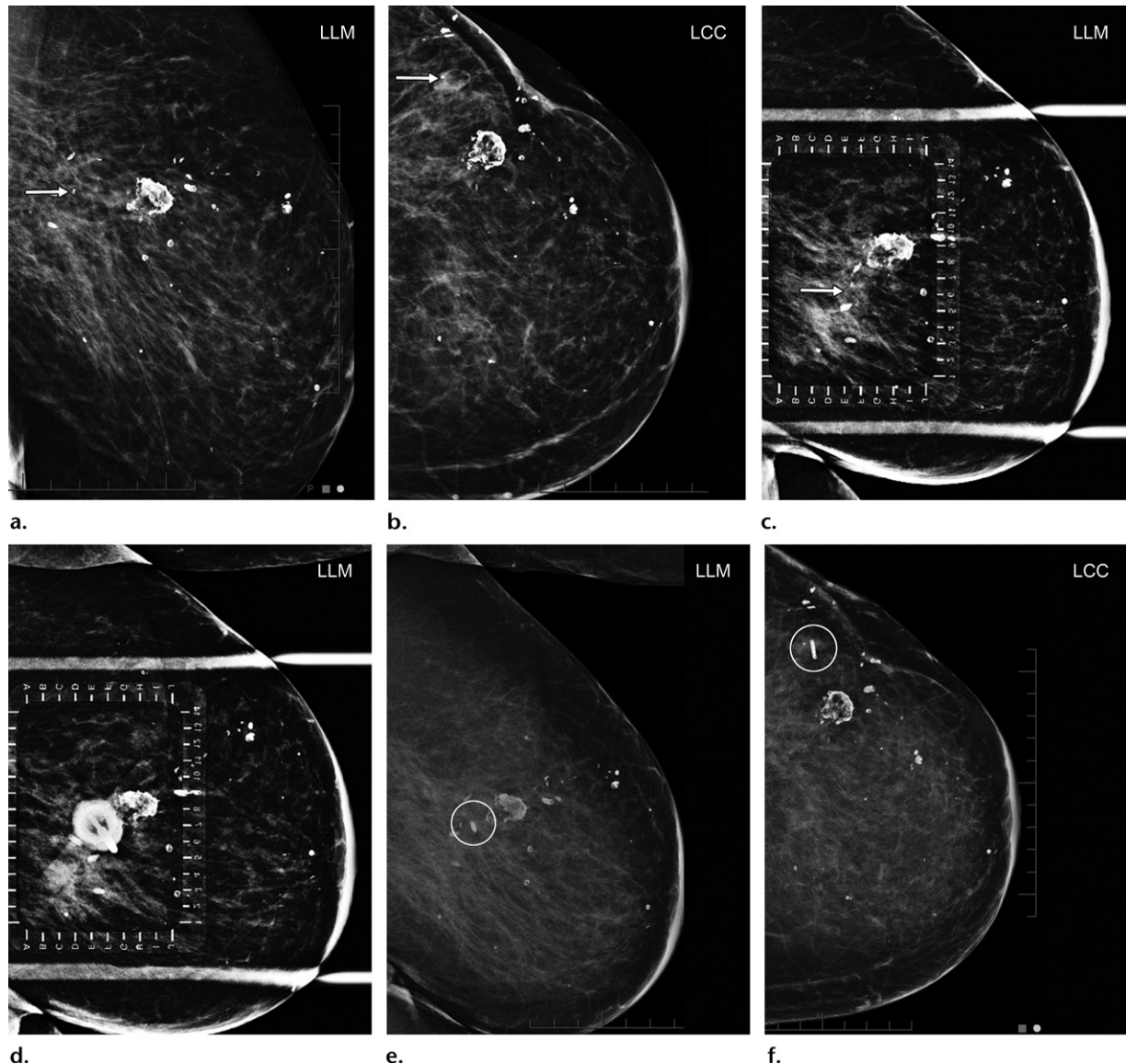
Breast localization with the RFID tag, a part of the LOCALizer localization system introduced in 2017, involves the use of radio waves to transfer information (44). The RFID tag measures  $9 \times 2$  mm and contains a ferrite rod wrapped in copper and a microprocessor enclosed in a biologically

inert glass casing within an antimigratory polypropylene sheath (44) (Fig 13). Each tag has a unique identification number that can be displayed on the RFID localizer reader device.

There are no known contraindications to using the RFID tag for breast localization (Figs 14, 15). However, at the time of this writing, it was not approved for placement in lymph nodes. If the RFID tag were used to localize an axillary lymph node, this would be considered off-label use (45). In one study (46), the clear surgical margin rate associated with RFID tag-guided excision was 97% in a subset of 33 patients with cancer.

In the OR, the surgeon uses a battery-powered RFID localizer reader that sends a 134.2-kHz radiofrequency signal to the RFID tag, which absorbs, modifies, and re-emits the signal (44). The re-emitted signal is received by the portable handheld localizer reader device, which is used directly in the operating field (46). The reader contains an integrated loop probe that can be used directly on the skin to determine the distance from the probe to the RFID tag.

There are two different modes of the reader device that can be used to reabsorb the signal: one with a 6-cm range loop probe and the other with a 3-cm range sterile surgical probe. Thus, the reader has a detection range of 3–6 cm (44). The reader with the integrated loop probe is reusable and can be draped for use in the sterile surgical environment, whereas the 3-cm-range surgical probe is a pencil-sized, single-use device (46). The



**Figure 14.** Findings after lumpectomy and radiation treatment in a 70-year-old woman with a history of ductal carcinoma in situ (DCIS) in 2010. In 2018, she underwent stereotactic biopsy with clip placement posterolateral to the lumpectomy site. Pathologic analysis revealed DCIS, and she underwent RFID tag localization of the biopsy clip. (a, b) LLM (a) and LCC (b) mammograms show a coil-shaped clip (arrow), marking the site of biopsy-proven DCIS, posterolateral to the lumpectomy site. (c) LLM mammogram with an alphanumeric grid shows the target clip (arrow). (d) LLM mammogram with an alphanumeric grid shows the hub of the tag applicator projecting over the clip. (e, f) LLM (e) and LCC (f) mammograms show successful RFID tag localization (circle) of the clip. (Case courtesy of Dr Priyanka Handa.)

small caliber of the surgical probe can be used in small incisions to guide the surgeon directly to the target without obscuring visualization (46). On the reader screen, the distance in millimeters from the probe to the RFID tag and the tag's unique identification number can be displayed. In addition, the reader emits an audible signal.

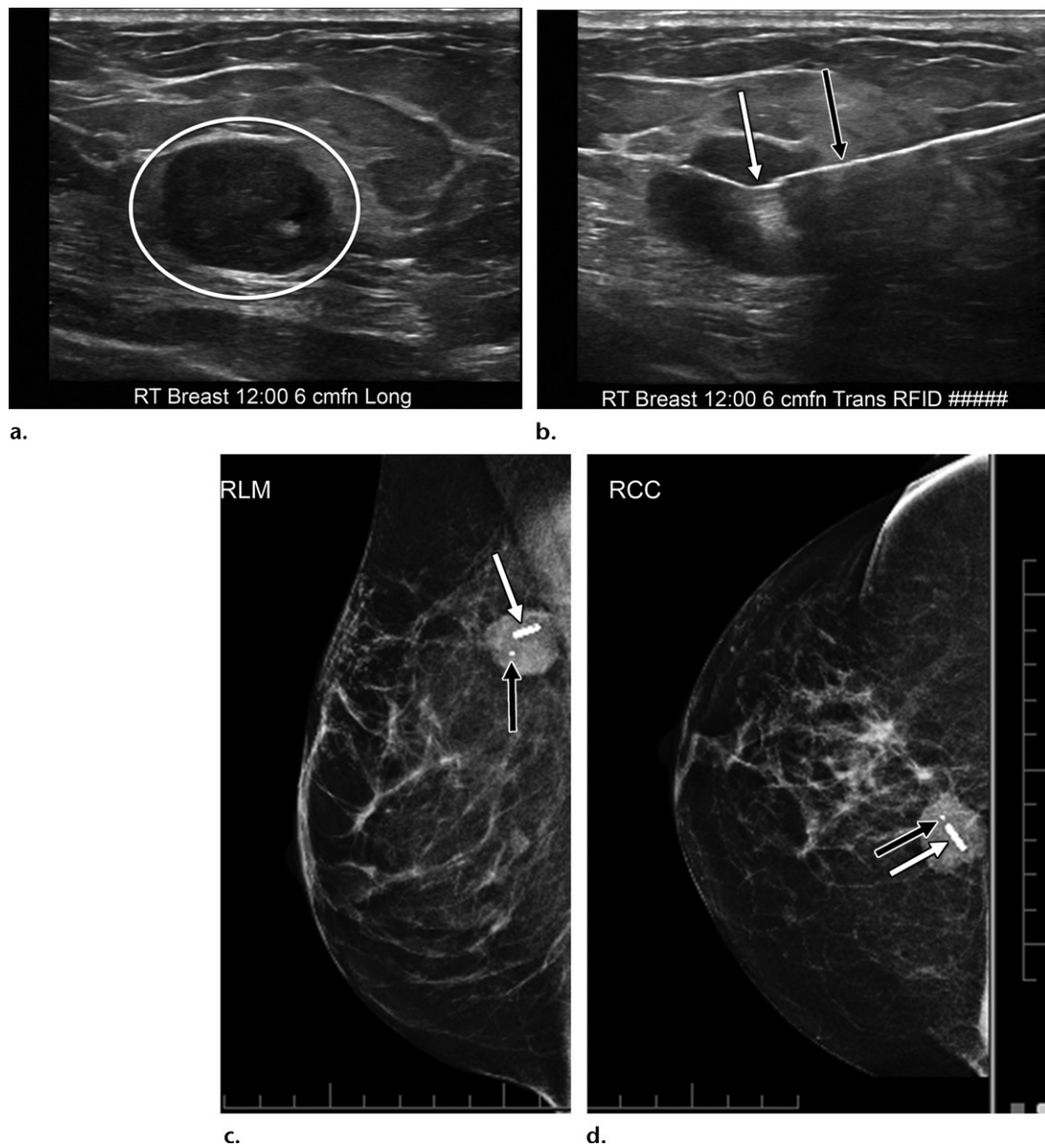
In an early feasibility study (44), no RFID migration was detected before the surgical incision; however, there was tag migration along the insertion track as the lesion was being retracted to make the final cut along the deep surface of the specimen. Since that study was performed, an antimigratory sheath has been added to the RFID device. In a more recent study (46), no

tag migration was found in any patients who underwent RFID localization. The RFID tag creates a 2.5-cm susceptibility artifact when imaging is performed using a gradient-echo pulse sequence in a 3-T MRI unit (45).

The advantages of using the RFID tag are similar to those of using other nonradioactive nonwire localization devices. Each RFID tag's unique identification number helps to identify the tags, as the identification number is displayed on the reader.

## Conclusion

Many techniques to aid in surgical excisions of nonpalpable breast lesions are available, and each



**Figure 15.** RFID tag localization in a 64-year-old woman with right breast intraductal carcinoma. (a) Static B-mode US image shows an oval hypoechoic right (RT) breast mass (oval) and an associated clip. *fn* = from nipple, *Long* = longitudinal. (b) Static B-mode US image shows deployment of the RFID tag (white arrow) from the tag applicator (black arrow) into the breast mass. *fn* = from nipple, *RT* = right, *Trans* = transverse. (c, d) Findings on RLM (c) and RCC (d) mammograms obtained after localization confirm the presence of the RFID tag (white arrow) within the mass and the associated biopsy clip (black arrow). (Case courtesy of Dr Priyanka Handa.)

offers distinct advantages and disadvantages. Wire localization is a safe, well-established, and widely accessible technique that has been used for decades. The wire localization device itself, as compared with newer nonwire devices, is relatively inexpensive. However, a major disadvantage of wire localization is that it can be performed only on the day of surgery. This can cause a delay in the surgery start time and thus translate into additional expenses.

In comparison, nonwire localization techniques allow the localization to be performed on a separate day, in advance of the surgery.

This decouples the imaging and surgery schedules, preventing imaging examination delays from affecting surgery start times. In addition, some of the known challenges related to the presence of a wire may be reduced or eliminated by using nonwire localization techniques. Use of nonwire localization techniques has the potential to reduce the amount of nontarget tissue removed, improve cosmesis, and improve the patient's experience in terms of comfort and scheduling flexibility.

Each nonwire localization technique has distinct strengths and weaknesses that must be

considered. Furthermore, any change in practice with regard to localization technique requires multidisciplinary collaboration and communication among the radiology, surgery, and pathology teams. This is an exciting time in breast imaging owing to the numerous localization techniques that are available to aid in the surgical excision of nonpalpable breast lesions.

**Acknowledgments.**—We thank Kelly Kage, MFA, CMI, for her assistance with the medical graphics in this article. We also thank representatives from Cianna Medical, Endomagetics, Hologic, and Isoaid for allowing us to include some of their product images and Dr Priyanka Handa for providing the RFID cases described in this article.

**Disclosures of Conflicts of Interest.**—**M.E.S.** *Activities related to the present article:* disclosed no relevant relationships. *Activities not related to the present article:* grant support from GE Healthcare as principal investigator in breast MRI research study, support from Endomagetics for collaboration in post-marketing study of Magseed and Sentimag localization devices. *Other activities:* disclosed no relevant relationships.

## References

1. Tabár L, Vitak B, Chen TH, et al. Swedish two-county trial: impact of mammographic screening on breast cancer mortality during 3 decades. *Radiology* 2011;260(3):658–663.
2. Bray F, Ferlay J, Soerjomataram I, Siegel RL, Torre LA, Jemal A. Global cancer statistics 2018: GLOBOCAN estimates of incidence and mortality worldwide for 36 cancers in 185 countries. *CA Cancer J Clin* 2018;68(6):394–424.
3. Hayes MK. Update on Preoperative Breast Localization. *Radiol Clin North Am* 2017;55(3):591–603.
4. Kopans DB. Breast imaging. 3rd ed. Baltimore, Md: Lippincott Williams & Wilkins, 2007.
5. Hall FM, Kopans DB, Sadowsky NL, Homer MJ. Development of wire localization for occult breast lesions: Boston remembrances. *Radiology* 2013;268(3):622–627.
6. Butler R. Preoperative magnetic, other nonradioactive localization. In: Berg WA, Leung JWT, eds. *Diagnostic imaging: breast*. 3rd ed. Philadelphia, Pa: Elsevier, 2019.
7. Chagpar A, Yen T, Sahin A, et al. Intraoperative margin assessment reduces reexcision rates in patients with ductal carcinoma in situ treated with breast-conserving surgery. *Am J Surg* 2003;186(4):371–377.
8. Landercasper J, Attai D, Atisha D, et al. Toolbox to Reduce Lumpectomy Reoperations and Improve Cosmetic Outcome in Breast Cancer Patients: The American Society of Breast Surgeons Consensus Conference. *Ann Surg Oncol* 2015;22(10):3174–3183.
9. Silverstein MJ, Recht A, Lagios MD, et al. Special report: consensus conference III—image-detected breast cancer: state-of-the-art diagnosis and treatment. *J Am Coll Surg* 2009;209(4):504–520.
10. Mayo RC 3rd, Kalambo MJ, Parikh JR. Preoperative localization of breast lesions: current techniques. *Clin Imaging* 2019;56:1–8.
11. Spillane RM, Whitman GJ, McCarthy KA, Hulka CA, Hall DA, Kopans DB. Computed tomography-guided needle localization of nonpalpable breast lesions: review of 24 cases. *Acad Radiol* 1996;3(2):115–120.
12. Butler R, Berg WA. Preoperative lesion localization, bracketing. In: Berg WA, Leung JWT, eds. *Diagnostic imaging: breast*. 3rd ed. Philadelphia, Pa: Elsevier, 2019.
13. Patel SN, Mango VL, Jadeja P, et al. Reflector-guided breast tumor localization versus wire localization for lumpectomies: a comparison of surgical outcomes. *Clin Imaging* 2018;47:14–17.
14. Shetty MK. Presurgical localization of breast abnormalities: an overview and analysis of 202 cases. *Indian J Surg Oncol* 2010;1(4):278–283.
15. Corsi F, Sorrentino L, Bossi D, Sartani A, Foschi D. Preoperative localization and surgical margins in conservative breast surgery. *Int J Surg Oncol* 2013;2013:793819.
16. Gray RJ, Salud C, Nguyen K, et al. Randomized prospective evaluation of a novel technique for biopsy or lumpectomy of nonpalpable breast lesions: radioactive seed versus wire localization. *Ann Surg Oncol* 2001;8(9):711–715.
17. Jakub J, Gray R. Starting a radioactive seed localization program. *Ann Surg Oncol* 2015;22(10):3197–3202.
18. SAVI SCOUT Reflector and Delivery System Instructions for Use. Cianna Medical. <https://www.ciannamedical.com/wp-content/uploads/2016/11/Instructions-for-Use-Reflector-Delivery-System.pdf>. Published 2016. Accessed May 8, 2019.
19. Alderliesten T, Loo CE, Pengel KE, Rutgers EJT, Gilhuijs KG, Vrancken Peeters MJT. Radioactive seed localization of breast lesions: an adequate localization method without seed migration. *Breast J* 2011;17(6):594–601.
20. Jadeja PH, Mango V, Patel S, et al. Utilization of multiple SAVI SCOUT surgical guidance system reflectors in the same breast: a single-institution feasibility study. *Breast J* 2018;24(4):531–534.
21. Price ER, Khoury AL, Esserman LJ, Joe BN, Alvarado MD. Initial clinical experience with an inducible magnetic seed system for preoperative breast lesion localization. *AJR Am J Roentgenol* 2018;210(4):913–917.
22. Goudreau SH, Joseph JP, Seiler SJ. Preoperative radioactive seed localization for nonpalpable breast lesions: technique, pitfalls, and solutions. *RadioGraphics* 2015;35(5):1319–1334.
23. Shin K, Caudle AS, Kuerer HM, et al. Radiologic mapping for targeted axillary dissection: needle biopsy to excision. *AJR Am J Roentgenol* 2016;207(6):1372–1379.
24. Kalambo M, Parikh JR. Implementing the SAVI SCOUT system in community radiology practice. *J Am Coll Radiol* 2017;14(9):1234–1238.
25. Loving VA, Edwards DB, Roche KT, et al. Monte Carlo simulation to analyze the cost-benefit of radioactive seed localization versus wire localization for breast-conserving surgery in fee-for-service health care systems compared with accountable care organizations. *AJR Am J Roentgenol* 2014;202(6):1383–1388.
26. Iodine-125 and Palladium-103 Low Dose Rate Brachytherapy Seeds Used for Localization of Non-Palpable Lesions. United States Nuclear Regulatory Commission. <https://www.nrc.gov/materials/miau/med-use/toolkit/seed-localization.html>. Published 2017. Accessed May 11, 2019.
27. McGhan LJ, McKeever SC, Pockaj BA, et al. Radioactive seed localization for nonpalpable breast lesions: review of 1,000 consecutive procedures at a single institution. *Ann Surg Oncol* 2011;18(11):3096–3101.
28. Gray RJ, Pockaj BA, Karstaedt PJ, Roarke MC. Radioactive seed localization of nonpalpable breast lesions is better than wire localization. *Am J Surg* 2004;188(4):377–380.
29. Hughes JH, Mason MC, Gray RJ, et al. A multi-site validation trial of radioactive seed localization as an alternative to wire localization. *Breast J* 2008;14(2):153–157.
30. Lovrics PJ, Goldsmith CH, Hodgson N, et al. A multicentered, randomized, controlled trial comparing radioguided seed localization to standard wire localization for nonpalpable, invasive and in situ breast carcinomas. *Ann Surg Oncol* 2011;18(12):3407–3414.
31. Zhang Y, Seely J, Cordeiro E, et al. Radioactive seed localization versus wire-guided localization for nonpalpable breast cancer: a cost and operating room efficiency analysis. *Ann Surg Oncol* 2017;24(12):3567–3573.
32. Sharek D, Zuley ML, Zhang JY, Soran A, Ahrendt GM, Ganott MA. Radioactive seed localization versus wire localization for lumpectomies: a comparison of outcomes. *AJR Am J Roentgenol* 2015;204(4):872–877.
33. Gilcrease MZ, Dogan BE, Black DM, Contreras A, Dryden MJ, Jimenez SM. Transection of radioactive seeds in breast specimens. *Am J Surg Pathol* 2016;40(10):1375–1379.
34. Mango V, Ha R, Gomberawalla A, Wynn R, Feldman S. Evaluation of the SAVI SCOUT surgical guidance system for localization and excision of nonpalpable breast lesions: a feasibility study. *AJR Am J Roentgenol* 2016;207(4):W69–W72.

35. Mango VL, Wynn RT, Feldman S, et al. Beyond wires and seeds: reflector-guided breast lesion localization and excision. *Radiology* 2017;284(2):365–371.
36. Falcon S, Weinfurter RJ, Mooney B, Niell BL. SAVI SCOUT® localization of breast lesions as a practical alternative to wires: outcomes and suggestions for trouble-shooting. *Clin Imaging* 2018;52:280–286.
37. Cox CE, Russell S, Prowler V, et al. A Prospective, Single Arm, Multi-site, Clinical Evaluation of a Nonradioactive Surgical Guidance Technology for the Location of Nonpalpable Breast Lesions during Excision. *Ann Surg Oncol* 2016;23(10):3168–3174.
38. Harvey JR, Lim Y, Murphy J, et al. Safety and feasibility of breast lesion localization using magnetic seeds (Magseed): a multi-centre, open-label cohort study. *Breast Cancer Res Treat* 2018;169(3):531–536.
39. Lamb LR, Bahl M, Specht MC, D'Alessandro HA, Lehman CD. Evaluation of a nonradioactive magnetic marker wireless localization program. *AJR Am J Roentgenol* 2018;211(4):940–945.
40. Teshome M, Wei C, Hunt KK, Thompson A, Rodriguez K, Mittendorf EA. Use of a Magnetic Tracer for Sentinel Lymph Node Detection in Early-Stage Breast Cancer Patients: A Meta-analysis. *Ann Surg Oncol* 2016;23(5):1508–1514.
41. Hersi A-F, Eriksson S, Ramos J, Abdsaleh S, Wärnberg F, Karakatsanis A. A combined, totally magnetic technique with a magnetic marker for non-palpable tumour localization and superparamagnetic iron oxide nanoparticles for sentinel lymph node detection in breast cancer surgery. *Eur J Surg Oncol* 2019;45(4):544–549.
42. Jeffries DO, Dossett LA, Jorns JM. Localization for Breast Surgery: The Next Generation. *Arch Pathol Lab Med* 2017;141(10):1324–1329.
43. Endomagetics. Magseed Information For Use. Cambridge, England: Endomagetics, 2018.
44. Dauphine C, Reicher JJ, Reicher MA, Gondusky C, Khalkhali I, Kim M. A prospective clinical study to evaluate the safety and performance of wireless localization of nonpalpable breast lesions using radiofrequency identification technology. *AJR Am J Roentgenol* 2015;204(6):W720–W723.
45. LOCALizer. faxitron website. <https://www.faxitron.com/product/localizer/>. Published 2018. Accessed May 8, 2019.
46. DiNome ML, Kusske AM, Attai DJ, Fischer CP, Hoyt AC. Microchipping the breast: an effective new technology for localizing non-palpable breast lesions for surgery. *Breast Cancer Res Treat* 2019;175(1):165–170.